

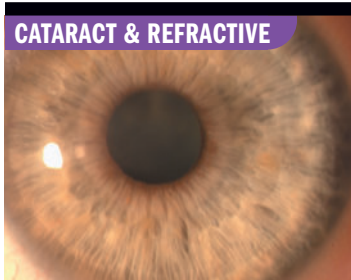
APRIL 2019 VOL. 15, NO. 3

### FOCAL POINTS

## A small benefit from Brexit to Commonwealth

Withdrawal could create more jobs for medical graduates from India

### CATARACT & REFRACTIVE



## Value of epithelial thickness mapping

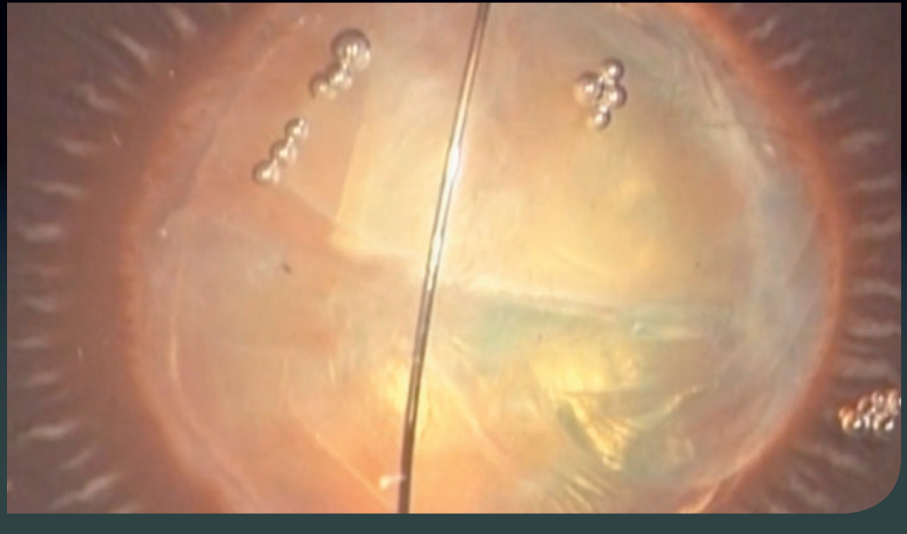
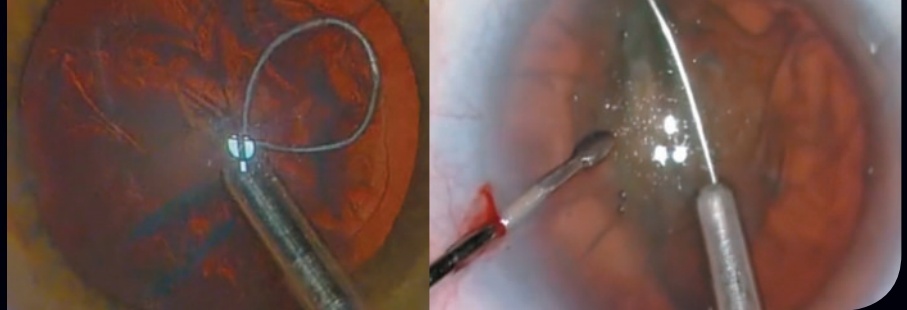
Epithelial-based approach can achieve unprecedented results

### RETINA

## Managing uveitis macular oedema

Intravitreal therapies superior for regional treatment

### IN VIEW



# Predicting effective IOL position

Lens fragmentation may avoid disrupting zonules, enhance refractive outcomes

PAGE 8

### IN VIEW

The lens fragmentation device is slid under the anterior capsule and brought midway to start halving the nucleus by retracting the loop. After halving the nucleus, the nucleus is rotated 90° to quarter it. (Images courtesy of ianTECH)

# Faros™

## MAKING THE DIFFERENCE WITH LEADING INNOVATION



NEW

### Precision and efficiency in eye surgery

The Faros surgical platform enables cataract, vitrectomy and glaucoma surgery of the highest level while constantly remaining comfortable and intuitively operable. The reliable flow control makes the surgeon's work even easier and safer than before. In addition, the Faros impresses with versatility, innovative technologies, exceptional functionality and ease of use.

- Available as an anterior platform or as a combined anterior/posterior platform
- Cutting-edge dual-pump system with flow and vacuum control with its unique SPEEPMode™
- Proven easyPhaco® technology
- Continuous Flow Cutter for traction-free vitreous body removal

Make the difference – with the new Faros:  
[www.oertli-instruments.com](http://www.oertli-instruments.com)

**EYE SURGERY. SWISS MADE.**

## Ophthalmology Times

EDITORIAL ADVISORY BOARD EUROPE

**Jorge L. Alió, MD, PhD**

Instituto Oftalmológico de Alicante,  
Alicante, Spain

**Winfried Amoaku**

University Hospital, Queen's Medical  
Centre, Nottingham, UK

**Gerd Auffarth, MD**

University of Heidelberg, Germany

**Albert Augustin, MD**

Klinikum Karlsruhe, Karlsruhe,  
Germany

**Rafael Barraquer, MD**

Institut Universitari Barraquer and  
Centro de Oftalmología Barraquer,  
Barcelona, Spain

**Christophe Baudouin, MD**

Quinze-Vingts National  
Ophthalmology Hospital, Paris,  
France

**Johan Blanckaert, MD**

Eye & Refractive Centre, Ieper,  
Belgium

**Burkhard Dick, MD**

Center for Vision Science, Ruhr  
University Eye Hospital, Bochum,  
Germany

**Christoph Faschinger, MD**

Medical University of Graz, Clinic of  
Ophthalmology, Graz, Austria

**Paolo Fazio, MD**

Centro Catanese di Medicina e  
Chirurgia (CCHC), Catania, Italy

**Alessandro Franchini, MD**

University of Florence, Eye Institute  
- Azienda Ospedaliera Careggi,  
Florence, Italy

**Frank Goes, MD**

Goes Eye Centre, Left Bank,  
Antwerp, Belgium

**Günther Grabner, MD**

University Eye Clinic Salzburg,  
Salzburg, Austria

**Zdenek Gregor, FRCS FRCOphth**

Moorfields Eye Hospital, London, UK

**Gábor Holló, MD, PhD, DSc**

Semmelweis University, Budapest,  
Hungary

**Vikentia Katsanevaki, MD**

Vardinogiannion Eye Institute,  
University of Crete, Greece

**Omid Kermani, MD**

Augenklinik am Neumarkt,  
Augenlaserzentrum Köln, Germany

**Hans-Reinhard Koch, MD**

Hochkreuz Augenklinik, Bonn,  
Germany

**Anastasios G.P. Konstas, MD, PhD**

1st University Department of  
Ophthalmology, AHEPA Hospital,  
Thessaloniki, Greece

**Pavel Kuchynka, MD**

Charles University, Prague, Czech  
Republic

**Erik L. Mertens, MD, FEBO**

Antwerp Eye Center, Antwerp,  
Belgium

**Norbert Pfeiffer, MD**

University of Mainz, Mainz, Germany

**Roberto Pinelli, MD**

Istituto Laser Microchirurgia  
Oculare, Brescia, Italy

**Matteo Piovella, MD**

C.M.A. srl Centro Microchirurgia  
Ambulatoriale, Monza, Italy

**Imola Ratkay-Traub, MD**

Danube Band Medical Centre,  
Hungary

**Herbert A. Reitsamer, MD**

Paracelsus University Salzburg,  
SALK  
University Eye Clinic, Salzburg,  
Austria

**Gisbert Richard, MD**

University Medical Center,  
Hamburg-Eppendorf, Hamburg,  
Germany

**Theo Seiler, MD**

Institut für Refraktive & Ophthalmo-  
Chirurgie (IROC) and University of  
Zurich, Zurich, Switzerland

**Tarek Shaarawy, MD**

University of Geneva, Geneva,  
Switzerland

**Sunil Shah, FRCOphth, FRCSEd,**

**FBCLA**  
Birmingham and Midland Eye Centre,  
Midland Eye Institute, Solihull, UK

**Gisèle Soubrane, MD**

Hôtel-Dieu Hospital, Paris, France

**David Spalton, MD**

St Thomas' Hospital & King Edward  
VII's Hospital, London, UK

**Einar Stefánsson, MD, PhD**

University of Iceland, National  
University Hospital, Reykjavik,  
Iceland

**John Thygesen, MD**

Copenhagen University Hospital  
Glostrup, Glostrup, Denmark

**Baha Toygar, MD**

Dünya Eye Hospital, Istanbul, Turkey

**Petja Vassileva, MD**

National Eye Institute, Sofia,  
Bulgaria

**Jan Venter, MD**

Optimax UK & Croydon Clinics, UK

**Carlos Vergés, MD, PhD**

C.I.M.A. Universidad Politécnic de  
Cataluña, Barcelona, Spain

**Paolo Vinciguerra, MD**

Istituto Clinico Humanitas, Rozzano,  
Milan, Italy

**Thierry Zeyen, MD**

University Hospital, Leuven, Leuven,  
Belgium

**EDITOR**

Caroline Richards  
CRichards@mmhgroup.com  
Tel: +44 (0) 2079 218 009

**EUROPEAN SALES MANAGER**

James Tate  
JTate@mmhgroup.com  
Tel: +44 (0) 2392 356 075

**SALES OPERATIONS ADMINISTRATOR**

Barbara Williams  
BWilliams@mmhgroup.com  
Tel: +44 (0) 151 353 3505

**DESIGN DIRECTOR**

Robert McGarr

**SENIOR GRAPHIC DESIGNER**

Lecia Landis

**AUDIENCE DEVELOPMENT MANAGER**

Kelly Kemper

**GROUP PUBLISHER**

Leo Avila  
LAvila@mmhgroup.com

**GROUP EDITORIAL DIRECTOR**

Sheryl Stevenson  
SStevenson@mmhgroup.com  
Tel: +1 (440) 891-2625

Hinderton Point, Lloyd Drive,  
Cheshire Oaks, Cheshire UK  
CH65 9HQ

Tel. +44 151 353 3500

**MISSION STATEMENT**

Ophthalmology Times Europe is the independent source for current developments and best practices in European ophthalmology. It is the balanced and unbiased forum for ophthalmologists to communicate practical experience, clinical knowledge, discoveries and applications, thereby promoting improvements to medical practice and patient health.

**Manuscripts:** All submissions will be handled with reasonable care, but the publisher assumes no responsibility for safety of artwork, photographs or manuscripts. Every precaution is taken to ensure accuracy, but the publisher cannot accept responsibility for the accuracy of information supplied herein or for any opinion expressed.

**Subscriptions:**

**Ophthalmology Times Europe is free to qualified subscribers in Europe.**

To apply for a free subscription, or to change your name or address, go to [www.oteurope.com](http://www.oteurope.com), click on Subscribe, & follow the prompts.

To cancel your subscription or to order back issues, please email your request to [fulfill@hcl.com](mailto:fulfill@hcl.com), putting OTE in the subject line. Please quote your subscription number if you have it.

**Reprints:** Licensing and Reuse of Content: Contact our official partner, Wright's Media, about available usages, license fees, and award seal artwork at [Advanstar@wrightsmedia.com](mailto:Advanstar@wrightsmedia.com) for more information. Please note that Wright's Media is the only authorized company that we've partnered with for MultiMedia Healthcare materials.

**Copyright 2019 MultiMedia Healthcare LLC (UK) all rights reserved.**

No part of this publication may be reproduced in any material form (including photocopying or storing it in any medium by electronic means and whether or not transiently or incidentally to some other use of this publication) without the written permission of the copyright owner except in accordance with the provisions of the Copyright, Designs & Patents Act (UK) 1988 or under the terms of a licence issued by the Copyright Licensing Agency, 90 Tottenham Court Road, London W1P 0LP, UK. Ophthalmology Times Europe (ISSN 1753-3066) and the logo appearing on the cover of this magazine are registered trademarks of MultiMedia Healthcare LLC. Applications for the copyright owner's permission to reproduce any part of this publication should be forwarded in writing to Permissions Dept, Hinderton Point, Lloyd Drive, Cheshire Oaks, Cheshire UK CH65 9HQ. Warning: The doing of an unauthorized act in relation to a copyright work may result in both a civil claim for damages and criminal prosecution.

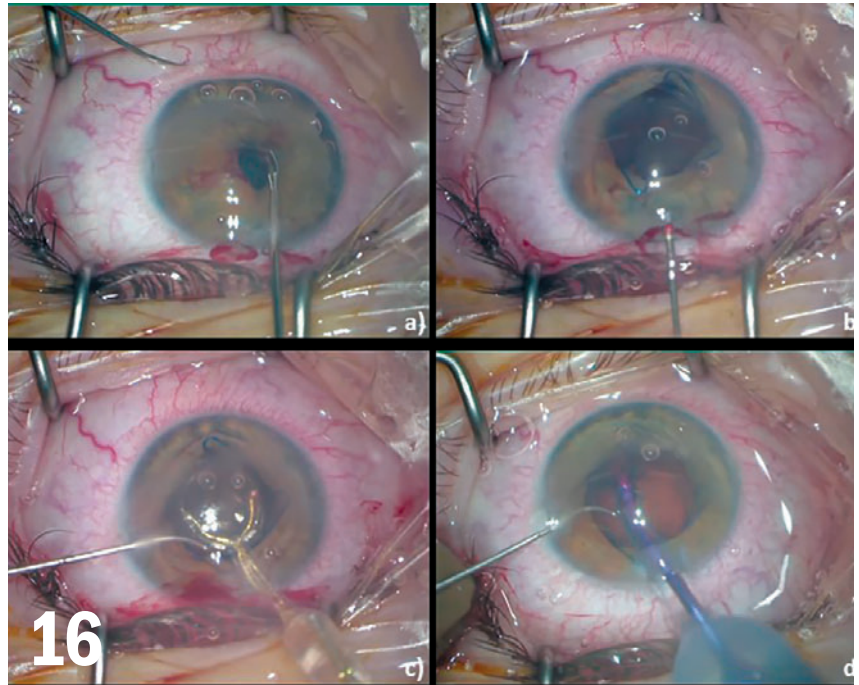
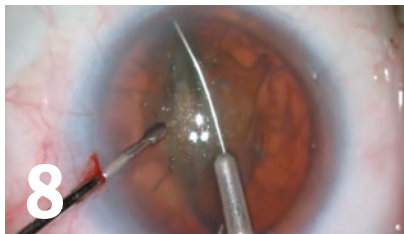
SUBSCRIBE ONLINE AT [www.oteurope.com](http://www.oteurope.com)

## ***Focal Points***

- 6 A small benefit from Brexit to Commonwealth ophthalmologists**  
 Brexit could create more jobs for medical graduates from India

## ***Issue Feature***

- 8 More stable surgery may help better predict effective IOL position**  
 Lens fragmentation device may avoid disrupting zonules, enhance refractive outcomes



- 12 An international encyclopedic database for IOL specifications**  
 The IOLCon platform optimises intraocular lens constants

- 14 New monofocal: improved intermediate vision and wider landing zone**  
 Same distance vision as standard aspheric monofocal, but better intermediate vision

- 16 Congenital cataract surgery: pupillary membrane and uveitis**  
 Surgery is complicated by pupillary membrane persistence, but tools can help

## ***Cataract & Refractive***

- 20 ETM valuable in surgical planning and evaluation of outcomes**  
 Measurements indicate the corneal epithelium plays a crucial role in outcomes

## ***Glaucoma***

- 28 Nitric-oxide-donating drugs: significant IOP lowering with once-daily dosing**  
 Advantages of nitric-oxide-donating drugs compared with timolol

## ***Retina***

- 30 Biologics may offer systemic therapy option for uveitis**  
 One biologic response modifier has indication for uveitis; several in development
- 32 Sustained-release corticosteroid expands armamentarium for uveitis**  
 FA implant effective in lowering recurrence rates through 12-month follow-up
- 34 Managing uveitic macular oedema**  
 Intravitreal treatments superior for regional treatment of disorder

- 36 Complex retinal detachment in presumed genetic vitreoretinopathy**  
 Optical coherence tomography (OCT) allows better surgical results

## ***Paediatrics***

- 38 Novel vision-screening tools aid children's needs worldwide**  
 New technologies help diagnosis in manner that is practical and adaptable



## ***Regulars***

- 42 Product news**

# NEW iMULTI POWER

PRESERVATIVE-FREE CONTROL  
NIGHT & DAY



# Cosopt<sup>®</sup> iMULTI

(20 mg/ml dorzolamide + 5 mg/ml timolol eye drops, solution)

## Abbreviated Prescribing Information

**Product Name:** COSOPT<sup>®</sup> Preservative-Free 20 mg/ml + 5 mg/ml, eye drops, solution, single-dose container. COSOPT<sup>®</sup> iMulti 20 mg/ml + 5 mg/ml eye drops, solution.

**Composition:** Each millilitre contains 20 mg dorzolamide (22.26 mg dorzolamide hydrochloride) and 5 mg timolol (6.83 mg timolol maleate). Please refer to the Summary of Product Characteristics (SmPC) for a full list of excipients.

**Indication:** Treatment of elevated intra-ocular pressure (IOP) in patients with open-angle glaucoma, or pseudoexfoliative glaucoma when topical beta-blocker monotherapy is not sufficient.

**Posology and Method of Administration:** One drop of COSOPT in the conjunctival sac of the affected eye(s), two times daily. If another topical ophthalmic agent is being used, administer COSOPT and the other agent at least ten minutes apart. COSOPT is a sterile solution that does not contain preservative. Safety in paediatric patients less than 2 years of age has not been established. Please see the SmPC for use in children of more than 2 years.

**Contraindications:** Hypersensitivity to any component of this medicine, reactive airway disease, including bronchial asthma, or a history of bronchial asthma, severe chronic obstructive pulmonary disease, sinus bradycardia, sick sinus syndrome, sino-atrial block, second- or third-degree atrioventricular block not controlled with pacemaker, overt cardiac failure, cardiogenic shock, severe renal impairment (CrCl <30 ml/min) or hyperchloraemic acidosis.

**Warnings and Precautions:** The same types of adverse reactions found with systemic administration of beta-blockers or sulphonamides may occur, these include severe reactions seen with sulphonamides such as Stevens-Johnson syndrome and toxic epidermal necrolysis. In patients with cardiovascular diseases (e.g. coronary heart disease, Prinzmetal's angina and cardiac failure) and hypotension, therapy with beta-blockers should be critically assessed and therapy with other active substances should be considered. Patients should be watched for signs of deterioration and adverse reactions. Beta-blockers should only be given with caution to patients with first degree heart block. Patients with severe peripheral circulatory disturbance/disorders (i.e. severe forms of Raynaud's disease or Raynaud's syndrome) should be treated with caution. Respiratory reactions, including death due to bronchospasm in patients with asthma have been reported following administration of some ophthalmic beta-blockers. Use with caution, in patients with mild/moderate chronic obstructive pulmonary disease (COPD) and only if the potential benefit outweighs the potential risk. Use with caution in patients with hepatic impairment. Concomitant use of dorzolamide with oral carbonic anhydrase inhibitors is not recommended. Use of two topical beta-adrenergic blocking agents is not recommended. Caution in patients subject to spontaneous hypoglycaemia or with labile diabetes. These signs and symptoms of acute hypoglycaemia and hyperthyroidism may be masked. Caution in patients with corneal diseases. The anaesthetist should be informed when a patient is receiving timolol as beta-blocking ophthalmological preparations may block systemic beta-agonist effects e.g. of adrenaline. Though no acid-base disturbances have been observed with COSOPT (preserved formulation), patients with a prior history of renal calculi may be at increased risk of urolithiasis. Patients with acute angle-closure glaucoma require therapeutic interventions in addition to ocular hypotensive agents. This medicinal product has not been studied with acute angle-closure glaucoma. Corneal oedema and irreversible corneal decompensation have been reported in patients with pre-existing chronic corneal defects and/or a history of intraocular surgery while using dorzolamide. Precautions should be used when prescribing in these groups of patients. Patients with a history of contact hypersensitivity to silver should not use COSOPT iMulti as dispensed drops may contain traces of silver from the container. This medicinal product has not been studied in patients wearing contact lenses. There is limited experience with COSOPT in infants and children. Please refer to the SmPC.

**Interactions with Other Medicinal Products:** There is a potential for additive effects resulting in hypotension and / or marked bradycardia when ophthalmic beta-blockers solution is administered concomitantly with oral calcium channel blockers, catecholamine-depleting drugs or beta adrenergic blocking agents, antiarrhythmics (including amiodarone), digitalis glycosides, parasympathomimetics, guanethidine, narcotics and monoamine-oxidase (MAO) inhibitors. Potentiated systemic beta-blockade (e.g. decreased heart rate, depression) has been reported during combined treatment with CYP2D6 inhibitors (e.g. quinidine, fluoxetine, paroxetine) and timolol. Mydriasis resulting from concomitant use of ophthalmic beta-blockers and adrenaline (epinephrine) has been reported occasionally.

**Pregnancy and Breast Feeding:** Do not use in pregnancy or during breast-feeding.

**Driving and using machines:** Possible side effects such as blurred vision may affect some patients' ability to drive and/or operate machinery.

**Undesirable Effects:** (Refer to SmPC for complete information on side effects). The side effects observed with COSOPT or one of its components include: headache, depression, burning and stinging, conjunctival injection, blurred vision, corneal erosion, ocular itching, tearing, eyelid inflammation, eyelid irritation, iridocyclitis, signs and symptoms of ocular irritation including blepharitis, keratitis, decreased corneal sensitivity and dry eyes and visual disturbances including refractive changes (due to withdrawal of miotic therapy in some cases), ptosis, bradycardia, syncope, sinusitis, dyspnoea, dysgeusia, nausea and dyspepsia, urolithiasis, signs and symptoms of systemic allergic reactions, including angioedema, urticaria, pruritus, rash, anaphylaxis, asthma/fatigue, hypoglycaemia, cardiac arrest, heart block, AV block, cardiac failure, chest pain, palpitation, oedema.

**Overdose:** Treatment should be symptomatic and supportive. Serum electrolyte levels (particularly potassium) and blood pH levels should be monitored.

**Special Precautions for storage:** Do not store above 25°C.

**Price:** COSOPT Preservative-Free 60 x 0.2ml, single-dose containers

£28.59; COSOPT iMulti 1 x 10ml bottle (60 days treatment) £28.00.

**MA Holder:** Santen Oy, Niittyhaankatu 20, 33720 Tampere, Finland.

**MA Numbers:** COSOPT Preservative-Free PL 16058/0015

COSOPT iMulti PL 16058/0025

**Legal Category:** POM

**Date of Prescribing Information:** September 2018.

**Job Code:** NP-CSPTPF-UK-0005

Adverse events should be reported. Reporting forms and information can be found at [www.mhra.gov.uk/yellowcard](http://www.mhra.gov.uk/yellowcard). Adverse events should also be reported to Santen UK Limited (Email: [medinfo@santen.co.uk](mailto:medinfo@santen.co.uk) or telephone: 0345 075 4863).

# A small benefit from Brexit to Commonwealth ophthalmologists

Brexit could create more jobs for medical graduates from India

By Erica Crompton;

Reviewed by  
Dr Dinesh Verma

It's not been widely reported in the UK media, more so in the Indian press, but some doctors coming from overseas—from outside Europe, in particular India—are welcoming Brexit as it may create more jobs for their medical graduates.

According to the *Hindustan Times*, Britain has long depended on doctors from India to work in the NHS, but reliance is likely to increase after the UK leaves the European Union (EU) and newly EU-trained doctors will no longer have the right to work here.<sup>1</sup>

India is the largest source country of doctors in the NHS after Britain—there are currently 25,281 doctors who gained their medical qualifications in India.

While some younger surgeons and students born in India are welcoming Brexit to improve their chances of a Tier 2 Visa stay in the UK, not everyone agrees Brexit will benefit Commonwealth surgeons, such as Dinesh Verma, MD, a former Consultant Ophthalmologist in the NHS and independent sector for over 25 years, including at Cambridge University Hospitals.

Like many ophthalmologists, Dr Verma qualified in India (MBBS in 1978 at Maulana Azad Medical College) and was awarded his MD in Ophthalmology in 1983, again in India, at the All India Institute of Medical sciences. He then migrated to the UK in the same year gaining a diploma in Ophthalmology from the Royal College of Surgeons of England in 1984 and an FRCS at Royal College of Surgeons of Edinburgh in 1985. Later in 1988, he achieved a FRCOphth.

“Personally, I voted to remain but I can see why a small majority from England voted for Brexit,” he said. “I believe it was mainly due to fear of mass uncontrollable immigration from Europe (and beyond via Europe) that triggered it but Brexiteers did not foresee the likely negative economic consequences.”

Britain has long depended on doctors from India to work in the NHS and Brexit will no-doubt impact on this, said Dr Verma: “Britain has long tradition of welcoming doctors from the Asian subcontinent, mainly for training purposes, but over last 25–30 years the cream of those coming for training were absorbed into the NHS, albeit either in middle

grade jobs or GP/Consultant only in areas of high demand, where white doctors didn't want to practice. There has recently been an increase in institutional racism as BME doctors have been competing for and demanding more leadership positions.”

“For ophthalmologists and other highly qualified medics from beyond the EU, Brexit may indeed level the playing field in terms of access to roles within the UK.” – McIndoe

Dr Verma's views on Brexit and how it will impact on the NHS and ophthalmology in the UK are echoed by Gary McIndoe, the founder and managing director of specialist business immigration law firm, Latitude Law.

McIndoe helps businesses across the UK to retain and attract outstanding international talent, and his company, Latitude Law, boasts the largest dedicated business immigration team in the north of England.

Following the Brexit vote, McIndoe and his team have been busy providing strategic advice and support to businesses concerned about their ability to recruit and retain international employees, both now and in the post-EU commercial environment. McIndoe is also a contributing author to the recently released book: ‘Doing Business After Brexit.’

Speaking exclusively to *Ophthalmology Times Europe*, McIndoe said: “Whilst in general, I believe

## IN SHORT

**An experienced consultant ophthalmologist and an expert immigration lawyer—both in the UK—explore potential Brexit benefits, if any, for eye surgeons born and trained in Commonwealth countries.**

Brexit to be a huge mistake, there can be no doubt that some people will benefit when the UK leaves the EU. From a corporate immigration perspective, the UK relies heavily upon foreign talent to help support and grow our economy. We need external workers covering all skill levels and across a very wide variety of sectors and industries. One sector hit particularly hard by the Brexit process has been healthcare, with one in 11 NHS posts currently unfilled, rising to one in eight across available nursing positions<sup>2</sup>.”

“Employee shortfalls will continue, and indeed probably worsen once we leave the EU, and what is less clear is how employers will source staff once free movement ceases. For ophthalmologists and other highly qualified medics from beyond the EU, Brexit may indeed level the playing field in terms of access to roles within the UK: once free movement of workers ends, all doctors and nurses wishing to work in the UK will have to apply for a Tier 2 visa, regardless of their country of origin.”

McIndoe reckons that the passporting of European medical qualifications may also end after Brexit, too, meaning that EU-qualified individuals will also be stripped of that benefit and will have to prove their capability in the same

way as any other non-EU applicants.

“These changes may encourage increased applications from Commonwealth countries such as Pakistan and India. It is worthwhile noting, however, that the £30,000 minimum salary requirement remains in place for Tier 2 visa applications, ensuring Brexit will only really benefit more highly qualified and senior practitioners,” said McIndoe.

Dr Verma agrees that Brexit could potentially create more job opportunities for senior ophthalmologists who have been born and studied in Commonwealth countries, he said: “Theoretically that is possible because before Brexit European doctors could just walk into a Consultant post with little surgical experience and minimal knowledge of spoken English while Indian doctors had to pass a rigorous qualifying examination to get GMC registration.”

These are the small, but still fringe benefits of Brexit. Commonwealth countries have always had a medical training program inspired and founded by Britain, said Dr Verma: “We have better communication skills and much larger surgical experience than our British or European counterparts.”

If this is the case, the UK

mainstream media haven’t widely reported any benefits to Brexit in terms of doctors, perhaps for unfounded fear of mass Asian immigrants if they hear that it will be easier after Brexit to get a visa to UK as a professional though. Said Dr Verma: “Personally I don’t think that will happen due to deep seated Institutional Racism in NHS which will only increase after Brexit.”

One thing is for sure, ophthalmology in the UK owes so much to Commonwealth-born eye surgeons who do so much for the NHS and other private practises. While it seems benefits to Brexit are slim-pickings, it is refreshing to read in the Indian media, that Brexit is offering hope to a few.

#### REFERENCES

1. <https://www.hindustantimes.com/world-news/uk-reliance-on-indian-doctors-likely-to-rise-post-brexit/story-ALvLtrbKpX9KYae3r8gPl.html>
2. <https://www.bmj.com/content/364/bmj.k5308>

#### DR DINESH VERMA, MD

*Dr Verma is founder/CEO of Dumfries Visonostics and senior advisor for Innovation & Technology, INCLIN Institute of Global Health. The author and contributors have no financial interests to declare.*

## DO YOU WANT TO SUBMIT AN ARTICLE TO OPHTHALMOLOGY TIMES EUROPE?

The emphasis of every article should be practical and current. Articles describing techniques should include enough information so that readers can make independent judgments about how applicable the approach is for them.

Articles usually contain 1,000 to 2,500 words, plus photos, graphs, charts, tables, diagrams or other appropriate graphics.

The typical time between an initial enquiry and a published magazine article is 1 to 3 months.

Articles must be original work that has not been published elsewhere. Articles are considered for publication with the understanding that they are not simultaneously under consideration for publication elsewhere.

Contact Caroline Richards, Editor, with questions at **CRichards@mmhgroup.com**

## More stable surgery may help better predict effective IOL position

Lens fragmentation device may avoid disrupting zonules, enhance refractive outcomes

By Dr Kenneth J. Hoffer and Dr Gerald J. Roper



Dr Hoffer



Dr Roper

Exacting IOL power calculations are required to provide optimal refractive results to patients following cataract surgery. One of the most common sources of error in these calculations remains the effective lens position (ELP). It is difficult to determine this exact healed postoperative axial position from preoperative biometric data.

The ELP may be reasonably estimated by the vector physics and mathematics of the latest IOL calculation formulas, although validating this specific parameter for error is limited by challenges in determining the postoperative axial IOL final lens position (FLP).

Going forward, swept-source ocular coherence tomography images on newer biometers may be able to help assess the accuracy of the ELP calculation parameter in the various formulas.

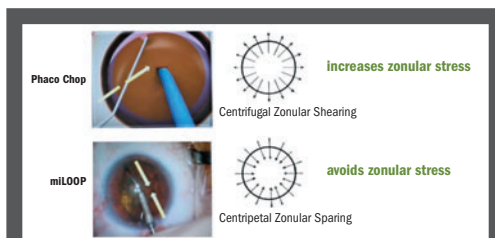
The FLP will be compared with the ELP estimates of the IOL axial position, presuming that surgical technique will not significantly influence zonular support.

We realise, however, that the surgery may well have an effect. In eyes that have had previous corneal surgery, it is also challenging to determine the exact power of the cornea.<sup>1</sup>

Formulas such as the Barrett Universal II, Haigis, Hoffer H-5, Holladay 2, Olsen, and others address more variables than in the past.<sup>2</sup>

### ELP still a surgical challenge

For as many advances as surgeons have at their disposal, both diagnostically and in the



(FIGURE 2) Centripetal nucleus disassembly with the lens fragmentation device (miLOOP).

SOURCE OF ERROR	CONTRIBUTION TO MAE
ELP: preoperative estimation of postoperative IOL position	36%
Postoperative refraction variability	27%
Preoperative axial length measurement	17%
Pupil size variation	8%
Variability in IOL power	1%

(FIGURE 1) Prediction of effective lens position (ELP) is the most common contributor to residual refractive error.<sup>3</sup> MAE, mean absolute error.

operating room, accurately achieving the desired postoperative refractive remains a challenge.

Further, surgeons' willingness to fully embrace premium lens solutions for their patients depends upon their comfort level with their results.

When patients are paying additionally for a truly refractive result from their implant surgery, surgeons are under pressure to nail outcomes precisely.

Disparities between the predicted ELP to the resultant FLP have been shown to contribute more than 35% of mean absolute error (MAE).<sup>3</sup> It is the most common cause of residual refractive error, followed by postoperative refraction variability, preoperative axial length measurement, and pupillary size variation (Figure 1).

### IN SHORT

► A lens fragmentation device can help to maintain zonular integrity, which can improve refractive outcomes, explain Drs Kenneth J. Hoffer and Gerald J. Roper.



# FEMTIS<sup>®</sup> Comfort

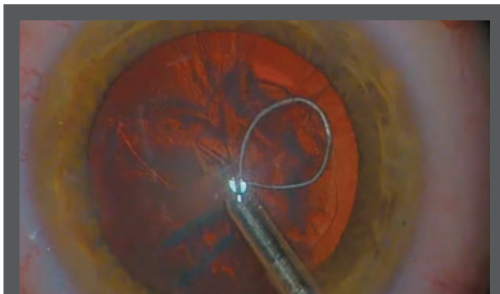**NEXT FRONTIER IN EDOF-IOL DESIGN:**

Turn your Automated Capsulotomies into Great Vision!

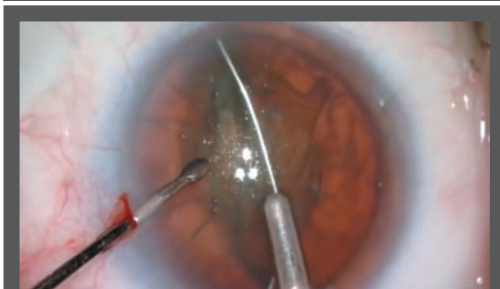Oculentis<sup>®</sup> Am Borsigturm 58 | 13507 Berlin | Germany

Phone. 030 43 09 55 0 | Fax. 030 43 09 55 11 | Web. [www.oculentis.com/femtis](http://www.oculentis.com/femtis)

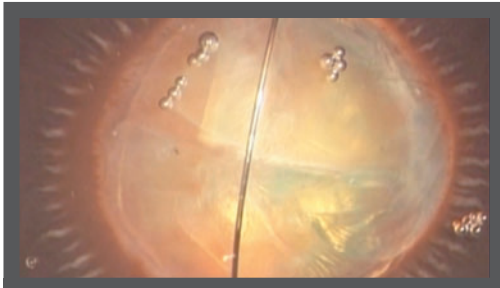




**(FIGURE 3)** The lens fragmentation device is being opened within the anterior chamber and edged under the anterior capsule to surround the nucleus. (Images courtesy of ianTECH)



**(FIGURE 4)** The lens fragmentation device has been slid under the anterior capsule and brought midway to start halving the nucleus by retracting the loop.



**(FIGURE 5)** After halving the nucleus, the nucleus is rotated 90° to quarter it. (Images courtesy of ianTECH)

A factor influencing the FLP, compared with the ELP, may be zonular integrity. Any part of the cataract procedure that strains the zonules or works against their integrity may contribute to less stability of the fibrosed lens capsule axial position and thus to less predictability of the refractive result.

Current investigations suggest that when zonular integrity is better

maintained for 360°, accuracy in achieving the refractive target seems to increase.

It would stand to reason that sagging due to zonular breaks or rupture would leave the lens in a different axial position and bearing from the anatomical predictions of ELP used to determine calculations.

Preoperative measurements that predict where the lens will sit after surgery presume intact zonules. Simply, if zonules break, ELP may become less accurate; that's our theory. By keeping the zonules intact, ELP prediction may be enhanced.

### Clinical experience

A recent comprehensive data set overview of 374 cataract surgery patients at Dr Roper's practice revealed an MAE of 0.23 D.

After considering the relationship between zonular integrity and ELP, the decision was made to incorporate the lens fragmentation device (miLOOP, Carl Zeiss Meditec/ianTECH).

The self-expanding, nitinol filament technology ensnares the nucleus allowing for full-thickness fragmentation.

It works independent of phaco energy, using instead centripetal (out-in) disassembly to minimise capsular stress and cut the nucleus in half. It was hoped that routine use of the device would avoid disrupting zonules and improve excellent refractive outcomes.

The device's sweeping motion along the inside of the lens capsule is a gentle manoeuvre, according to Dr Roper.

There was no significant decrease in zonular integrity observed throughout the surgical cases, and the learning curve was relatively short.

A data review of the clinic's first 50 miLOOP cases for 8-week refractive outcomes, using otherwise usual protocol and identical criteria as previous cases. The MAE dropped to 0.15 D.

### More confident recommendations

With the lens fragmentation

device, under the proper technique, there is little front to back or translational displacement of the lens when it is placed in the capsular bag (Figure 2).

By incorporating the lens fragmentation device, surgeons may enhance their cataract surgery process and move closer to delivering excellent refractive outcomes to patients (Figures 3–5).

More predictable results may allow surgeons to more fully participate in recommending and implanting premium IOL technology.

### Conclusion

Maintaining zonular integrity may help conquer one of the issues that holds surgeons back from achieving more accurate refractive outcomes on a consistent basis.

The lens fragmentation device is a tool that may enhance zonular integrity and perhaps the refractive outcomes. These factors may help to ensure the lens is placed in its intended position.

### REFERENCES

1. Savini G, Hoffer KJ. Intraocular lens power calculation in eyes with previous corneal refractive surgery. *Eye Vis (Lond)*. 2018;5:18. doi: 10.1186/s40662-018-0110-5. eCollection 2018.
2. Hoffer KJ, Savini G. Clinical results of the Hoffer H-5 formula in 2707 eyes: First 5th-generation formula based on gender and race. *Intl Ophthalmol Clin*. 2017;57:213-219. doi: 10.1097/IIO.0000000000000183.
3. Norrby S. Sources of error in intraocular lens power calculation. *J Cataract Refract Surg*. 2008;34:368-376.

#### DR KENNETH J. HOFFER, MD, FACS

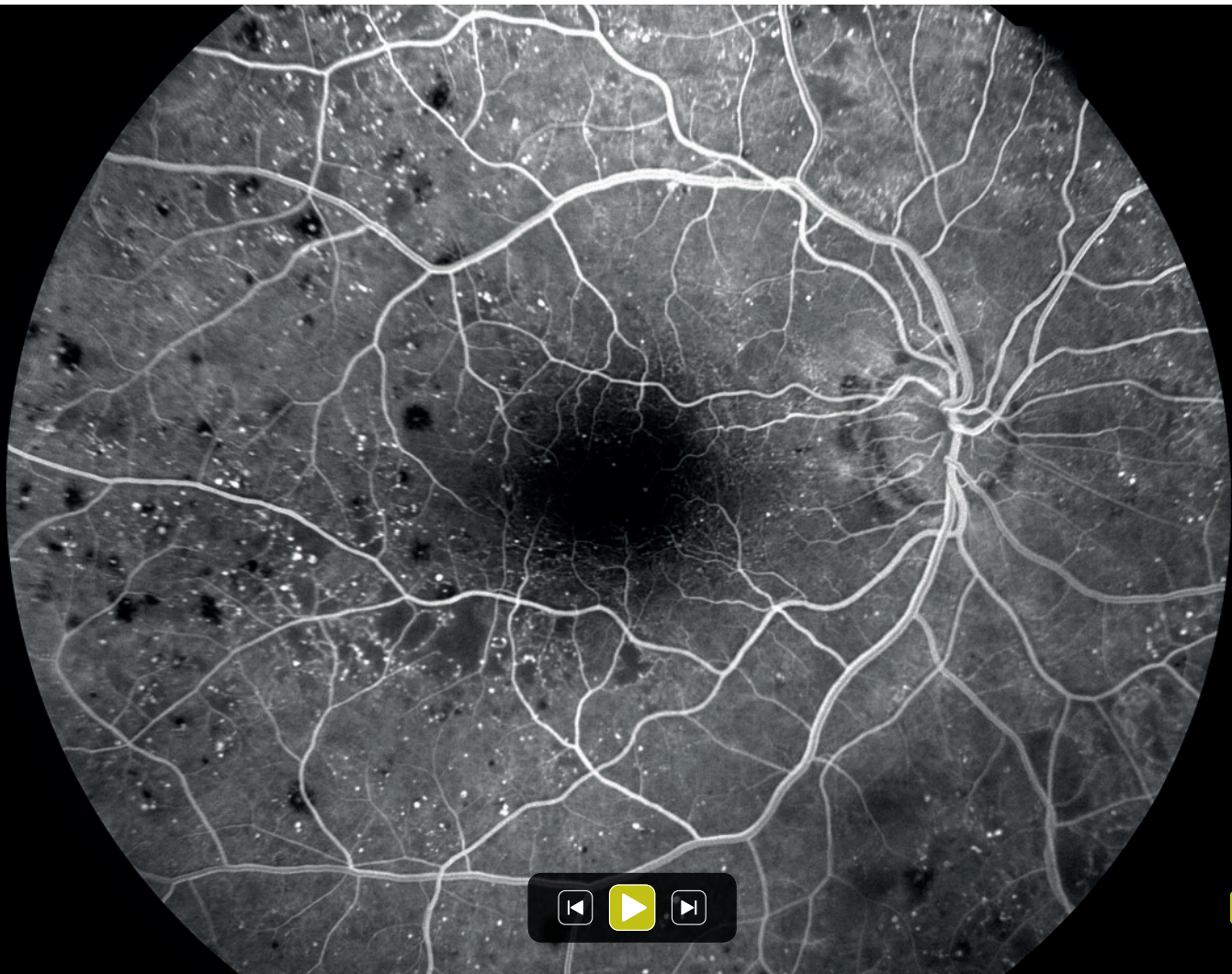
e: [khoffermd@aol.com](mailto:khoffermd@aol.com)

Dr Hoffer is a clinical professor of ophthalmology at Jules Stein Eye Institute, University of California, Los Angeles. He did not indicate any proprietary interest in the subject matter.

#### DR GERALD R. ROPER, MD

e: [ropergj@gmail.com](mailto:ropergj@gmail.com)

Dr Roper is in private practice at Advanced Eye Care, Batesville, IN. Dr Roper is a consultant to ianTECH.



Do you think **Dynamic Fluorescein Angiography** is crucial in providing **VALUABLE INFORMATION** of retinal Blood Flow?

**YES**

**we completely agree!**

eidon Fa

The **Automatic Dynamic Fluorescein Angiography** System

For more info visit our website

# An international encyclopedic database for IOL specifications

The IOLCon platform optimises intraocular lens constants

By **Lynda Charters;**

Reviewed by **Dr Achim Langenbucher**



Dr Langenbucher

**W**hen choosing intraocular lenses (IOLs) for implantation after cataract surgery, surgeons know all too well the challenges of this task and that one power does not fit all, numerous parameters are involved, and in some cases, despite the best of intentions, postoperative surprises have occurred all too frequently during the evolution of the art of choosing the optimal IOL for implantation.

## **The basis of IOLCon**

“The patient’s visual needs and the biometry of the individual eye are prime considerations when picking an IOL. The IOL constants are the important components that link the biometric measurements to the expected axial lens position in the eyes. An accurate estimation of this effective lens position is needed to determine which IOL power is best suited for an individual patient,” said Achim Langenbucher, PhD.

The realisation of the complexity of obtaining the best fit led to the development of IOLCon, an open-to-all online database that continuously compiles and optimises IOL constants for optimal implantation outcomes after cataract surgery.

Dr Langenbucher explained that “the concept of IOLCon as an encyclopedic database for IOL specifications is evolving in cooperation with the manufacturers of IOLs and biometry devices as well as with cataract surgeons from all around the world.” Dr Langenbucher is chair of Experimental Ophthalmology, Saarland University, Institute of Experimental Ophthalmology, Homburg/Saar, Germany.

## **Why optimise the IOL constants?**

Because they are the keys to choosing the correct IOL powers. “The choice of IOL powers can be improved through continuous optimisation of IOL constants. Reliable IOL constants require a high number of preoperative biometry measurements together with the respective refractive outcomes. A continuously growing database of refractive success will ensure the increasing reliability of the IOL calculations.”

## **How IOLCon works**

He explained that the IOLCon platform is based on a PostgreSQL database system. The user-interface and the optimisation algorithms were programmed in the Hypertext Preprocessor language. Optimisation algorithms for the published IOL formulas, i.e., SRK II, SRK/T, Haigis, Hoffer Q, and Holladay 1, were implemented. The graphical user interface provides a tabular listing of IOL specifications and nominal as well as optimised IOL constants.

Two user groups can enter the data. A registered, authorised staff member employed by the IOL manufacturer or distributor can enter the technical data for their IOL products; the responsibility lies with the manufacturers and distributors to maintain the most up-to-date product information.

Cataract surgeons can search IOLCon for one or more IOLs based on the required specifications and available power ranges. A search option allows filtering according to various criteria such as manufacturer, material, and optic size. Registered surgical centres can upload preoperative and postoperative refractive results via open text file formats to obtain globally or personally optimised IOL constants. The uploaded files can contain the results of different IOLs, devices, or ethnicities. Optimisation will be performed according to the needs of the patients using only data obtained with a specific biometer or by the surgeon when sufficient data are available,” Dr Langenbucher emphasised.

IOLCon currently includes data from more than 310 IOL models manufactured by 23 different companies. Optimised constants are available for 61 IOL models (based on almost 9,000 clinical results). For greater

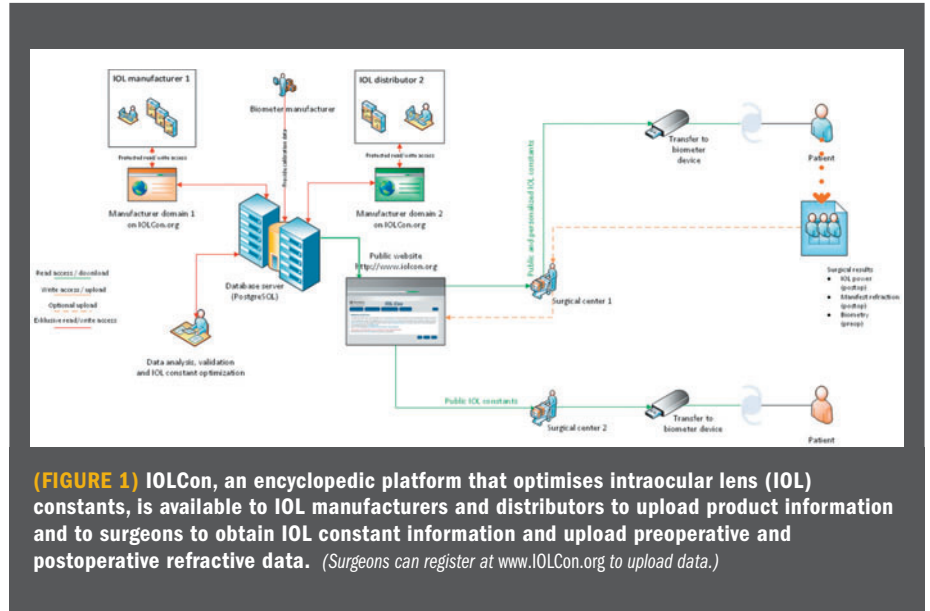
## **IN SHORT**

► **IOLCon is an open-to-all online database that continuously compiles and optimises IOL constants for optimal implantation outcomes after cataract surgery.**

convenience, the biometry device manufacturers are implementing the platform's open XML interface to integrate IOLCon with their devices.

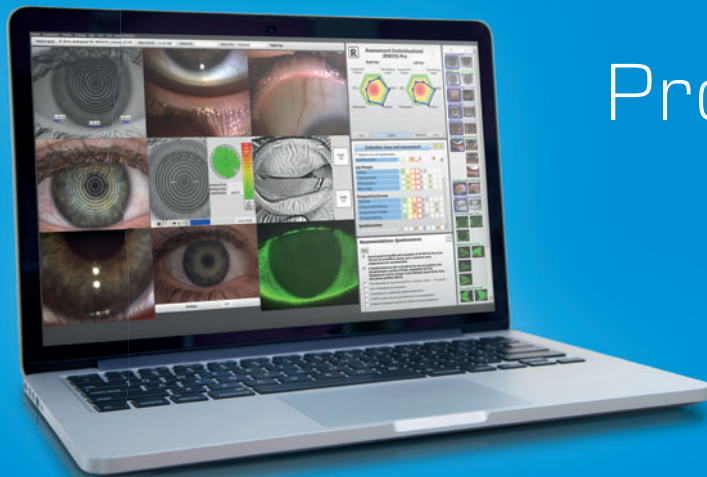"The use of the platform is free of charge for registered ophthalmic surgeons. The more data that ophthalmic surgeons upload to the platform, the more reliable the optimised constants will be. In the near future, IOLCon will be available for rapid worldwide dissemination of optimised IOL constants," Dr Langenbucher concluded.

Surgeons can register at [www.IOLCon.org](http://www.IOLCon.org) to upload data.



**DR ACHIM LANGENBUCHER, PHD**

E: [achim.langenbucher@uks.eu](mailto:achim.langenbucher@uks.eu)  
 Dr Langenbucher has no financial interests in any aspect of this report.



# Your Professional Dry Eye Assistant

## OCULUS Keratograph 5M with JENVIS Pro Dry Eye Report: All relevant information at a glance!

Dry eye management has never been this easy. The new JENVIS Pro Dry Eye Report helps you perform comprehensive screenings, using the measuring results as a basis for diagnosing dry eye syndrome. The workflow is optimized for time saving and patient friendliness. All results are documented and summarized for you and your patient in a neat and easily understandable printout.



[www.ocus.de](http://www.ocus.de)

Follow us!



# Novel monofocal IOL technology improves intermediate vision

New lens provides high-quality distance vision, improved intermediate vision

By Cheryl Guttman  
Krader

Reviewed by Dr Oliver  
Findl



Dr Findl

Findings from optical bench testing and clinical experience demonstrate that the new enhanced monofocal IOL, model ICB00 (TECNIS Eyhance IOL, Johnson & Johnson Surgical Vision [JJSV]), meets its design goals in having the same distance image quality and photic phenomena profile of a conventional aspheric monofocal lens plus improved intermediate vision as an added benefit.

Based on positive early experience with the ICB00, Oliver Findl, MD, told *Ophthalmology Times Europe* that he has adopted the new IOL as his standard monofocal lens.

“After bilateral ICB00 implantation, patients are achieving very good unaided distance visual acuity, even when emmetropia is not achieved. Many patients have very good unaided intermediate vision and often they are able to read small print without correction at a range of 45 to 50 cm, particularly with good lighting. In addition, no patient so far has complained about nighttime dysphotopsias,” said Dr. Findl MD, MBA, Chief of Department of Ophthalmology, Hanusch Hospital Vienna.

“Considering its performance, I consider the ICB00 a very attractive choice.”

Dr. Findl stated that transitioning to the ICB00 has been easy because it is based on a time-tested and familiar platform.

“The new lens has the same hydrophobic acrylic material, corneal spherical aberration correction, haptic design, shooter, and A-constant as the TECNIS ZCB00 aspheric monofocal IOL. Consequently, there was no need to change routines for planning or performing the surgery, which is a real advantage when using new technologies,” he said.

He added that he has kept the idea of “underpromise and overdeliver” in mind as he implements the new enhanced monofocal IOL as his standard monofocal implant.

“I am not raising patient expectations for visual performance after surgery, but I hope that by using the ICB00 as my standard lens in all monofocal cases, I will get slightly better functional outcomes and

slightly happier patients than I have in the past,” Dr. Findl explained.

## Novel technology

The ICB00 features a continuous higher-order aspheric surface that results in a continuous power change from the center of the lens to the periphery.

“Whereas power in the ZCB00 increases from the periphery to the center of the lens, the power change in the ICB00 is continuous, but faster, with most of the change occurring in the central part of the lens,” explained Aixa Alarcon, PhD, senior research scientist, JJSV, Groningen, The Netherlands.

Findings from a series of optical bench testing demonstrate how the ICB00 is distinguished from the ZCB00 and other hydrophobic acrylic monofocal IOLs in its optical and predicted visual performance. Results from modulation transfer function (MTF) measurements in a model eye simulating average corneal spherical and chromatic aberration showed that the MTF was highest for the TECNIS ZCB00 and similar for the ICB00, AcrySof SN60WF (Alcon), Clareon CNZ0T (Alcon), and Vivinex XY1 (Hoya) for 3 mm pupil size. When the pupil size was increased to 5 mm to simulate low light conditions, however, the MTF for the ICB00 was about 30% better compared with the Clareon lens and about 45% better than the Vivinex lens.

“These data suggest better contrast sensitivity with the ICB00 under low light conditions,” said Dr. Alarcon.

In simulated visual acuity (VA) testing, the ICB00 provided distance VA better than 20/20 and intermediate VA (66 cm) that was about 1 line better than the ZCB00 IOL. Same results were also found in

## IN SHORT

► A new monofocal IOL provides high-quality distance vision and improved intermediate vision compared with a conventional aspheric monofocal IOL.

the clinical study. In addition, photic phenomena were assessed using the eye model and showed no differences between the ICB00 and ZCB00 IOLs.

“We found no halos around the main image or increase in scatter with the ICB00 IOL. Therefore, we expect that the enhanced monofocal IOL would be associated with similar photic phenomenon as the ZCB00, as it was found in the clinical study,” Dr. Alarcon said.

### Clinical performance

Results from a prospective, multicenter, randomized, masked clinical trial comparing the ICB00 and ZCB00 IOLs and from real-world clinical experience are consistent with the findings of the bench studies, said Joy Domingo, MD, Global Medical Director, Cataract, JJSV, Santa Ana, CA.

The randomized trial was conducted at nine sites across Europe. Enrolled patients received either the ICB00 or the ZCB00 bilaterally and were followed to 6 months.

Analyses of data collected at the end of the study showed patients implanted with the ICB00 had significantly better monocular and binocular intermediate vision compared with the ZCB00 group. In monocular testing, mean logMAR distance-corrected intermediate VA (DCIVA) was 0.19 for the ICB00 and 0.31 for the ZCB00 (difference of 1.1 lines  $P < .0001$ ). The ICB00 was also associated with a 1.1 line improvement ( $P < .0001$ ) in mean logMAR uncorrected IVA (UCIVA) compared with the ZCB00 (0.16 vs. 0.27). In binocular testing, the ICB00 maintained its statistically significant advantage compared with the ZCB00 in analyses of both mean logMAR DCIVA (0.09 vs 0.20; 1.1 line difference  $P < .0001$ ) and UCIVA (0.07 vs. 0.17; 1.0 line difference  $P < .0001$ ).

Mean logMAR BCDVA was better than 0.0 in both monocular and binocular testing with both IOLs and comparable in the two groups.

Visual function was also

investigated using a questionnaire that was completed by 39 patients implanted with the ICB00 and 40 patients in the ZCB00 group. One item asked patients about difficulty seeing at 6 meters when walking on uneven surfaces, and a significantly higher percentage of ICB00 patients than ZCB00 patients reported having no difficulty (95% vs. 78%). Data collected in the study also showed no statistically significant differences between the two IOL groups in rates of halo, glare or starburst.

“We know that patients implanted with monofocal IOLs can still experience halos and glare, but these photic phenomena are rare and generally not debilitating. Because the ICB00 has no rings or zones, I anticipate that patients will not have complaints related to dysphotopsias with this lens,” commented Dr. Findl.

Oege Goslings, MD, PhD, is 1 of 18 high-volume TECNIS monofocal IOL surgeons chosen to participate in the initial commercial launch of the ICB00. He analyzed outcomes in his first 25 patients who underwent bilateral surgery. All of the patients had senile cataract, were free of ocular comorbidities, and had minimal to no corneal astigmatism.

Dr. Goslings reported that average distance BCDVA was 20/20, and UCDVA was good, even as high as 30/20 for some patients. Defocus curve testing in his patients showed mean decimal UCVA was 0.8 at -1.0 D and 0.62 at -1.5 D.

“The UCDVA outcomes are similar for patients implanted with the ICB00 compared with the ZCB00, but the ICB00 has a flatter and broader defocus curve. Consistent with that patients achieve better intermediate vision with the ICB00 and it is possible to achieve very good distance vision in a larger group of patients, even in cases where the target of emmetropia is not reached after surgery,” said Dr. Goslings, Elisabeth TweeSteden Hospital, Tilburg, The Netherlands.

Outcomes from 149 patients

operated on by surgeons participating in the ICB00 initial launch also showed good or very good distance vision and that patients were able to perform various intermediate vision tasks without wearing glasses.

“Patients reported being able to drive, even at night, shop, watch TV, cook, eat, play cards, work at the computer, and play the piano and other instruments. They also indicated feeling more confident while walking, particularly descending stairs,” said Dr. Goslings.

Spontaneous comments from individual patients were particularly interesting, he added.

“One patient who had the ZCB00 implanted in the first eye before the ICB00 was available noted having better intermediate vision with the ICB00 eye. Another patient bilaterally implanted with the ICB00 remarked that she was able to see more while cooking and eating than her husband who had the ZCB00,” Dr. Goslings said.

### Expanding role

Because of its efficacy and safety profile, Dr. Findl said he has just begun to use the ICB00 in a micromonovision approach for patients who are interested in presbyopia correction, but are not considered good candidates for a diffractive presbyopia-correcting IOL.

“My hope is that by aiming for emmetropia in the dominant eye and for slight myopia of about -0.5 D, in the nondominant eye, I can provide these patients with a little more functional vision without any drawbacks,” Dr. Findl said.

#### DR OLIVER FINDL, MD, MBA

**E:** [oliver@findl.at](mailto:oliver@findl.at)

*Dr Findl is Chief of the Department of Ophthalmology at Hanusch Hospital in Vienna, Austria. He is a paid scientific advisor to Johnson & Johnson Vision.*

# Congenital cataract surgery: pupillary membrane and uveitis

Surgery is complicated by pupillary membrane persistence, but tools can help

By Dr Florian T. A. Kretz

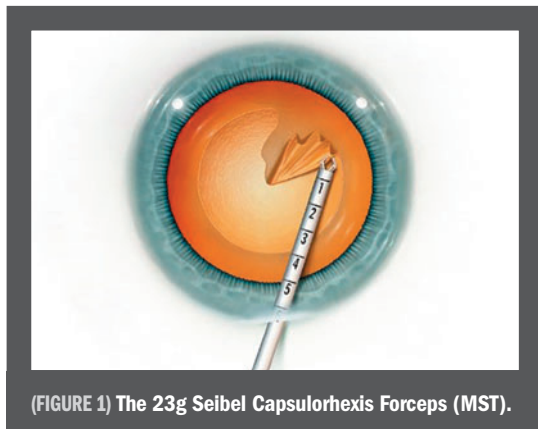**O**pacification of an eye's crystalline lens can lead to vision loss and an impaired quality of life for any patient. In paediatric congenital cataract, this can be a frightening experience for the child, and treatment will involve both them and their parents.

Dr Park, Assistant Professor of Ophthalmology at Johns Hopkins University School of Medicine, Wilmer Eye Institute, Baltimore, suggests: "Paediatric cataract surgery is different to adult cataract surgery, mainly due to the small size of the child's eye, with an axial length of 16.4 mm instead of 24 mm on average in adults, and the anterior chamber is only about 2 mm deep. The low scleral rigidity makes it difficult to maintain the chamber during surgery. In children, the sclera is about four times more pliable and has only half the tensile strength of the adult sclera."<sup>1</sup>

To date, congenital cataract has been one of the most challenging surgeries I have performed. The two cases discussed here were both difficult; however, the micro-instruments from MicroSurgical Technology (MST) deliver a more confident ability to perform a smoother, more controlled surgery.

## Background

David Yorston of Moorfield's Eye Hospital, London, suggests that, although in many cases of childhood



(FIGURE 1) The 23g Seibel Capsulorhexis Forceps (MST).

cataract the exact cause is unknown, there can often be an associated systemic condition, such as:

- ✦ Prenatal (intra-uterine) infection, e.g. rubella, cytomegalovirus, syphilis.
- ✦ Prenatal (intra-uterine) drug exposure, e.g. corticosteroids, vitamin A.
- ✦ Prenatal (intra-uterine) ionising radiation, e.g. X-rays.
- ✦ Prenatal/perinatal metabolic disorder, e.g. maternal diabetes.
- ✦ Hereditary (isolated: without associated eye or systemic disorder), e.g. autosomal dominant inheritance.
- ✦ Hereditary with associated systemic disorder or multi-system syndrome.
- ✦ Chromosomal, e.g. Down's syndrome (trisomy 21), Turner's syndrome.
- ✦ Skeletal disease or muscle disorder, e.g. Stickler syndrome, myotonic dystrophy.
- ✦ CNS disorder, e.g. Norrie's disease.
- ✦ Renal disease, e.g. Lowe's syndrome, Alport's syndrome.
- ✦ Mandibulo-facial disorder, e.g. Nance-Horan cataract-dental syndrome.
- ✦ Dermatological disorder, e.g. congenital ichthyosis, incontinentia pigmenti.<sup>2</sup>

Where unilateral cataracts are not inherited or associated with a systemic disease, they are usually the result of local dysgenesis and may be associated with other ocular dysgenesis such as persistent foetal vasculature (PFV), posterior lenticonus or lentiginosus.<sup>3</sup>

## Case 1: unilateral congenital cataract

A 6-year-old boy came to me with unilateral congenital cataract, with a refraction of +8 D and a pre-operative best corrected distance visual acuity of 0.5 logMAR. He had already been sent away from

## IN SHORT

► Tools to aid surgery for congenital cataract are discussed, along with case studies.



**Table 1. Postoperative results**

	1 DAY	1 MONTH	12 WEEKS	18 MONTHS
UDVA	0.4	0.4	0.5	0.5
CDVA		0.3	0.15	0.2
UNVA			0.5	0.4
DCNVA			0.1	0.15

**LogMAR values are given. UDVA, uncorrected distance visual acuity; CDVA, corrected distance visual acuity; UNVA, uncorrected near visual acuity; DCNVA, distance-corrected near visual acuity.**

two other clinics. Cataract surgery in such a case is surgically challenging because of increased scleral elasticity, thicker corneas and eye rubbing. Further, during surgery, children placed under general anaesthetic tend to turn up their eye globe, which makes the anterior segment of the eye squashed for space and surgery difficult. Postoperatively, issues such as reduced compliance with activity restriction, and the effect of postoperative astigmatism on amblyopia also must be considered.

Intraocular lens (IOL) selection was also problematic as the child was hyperopic. The choice of lens power is paramount to visual rehabilitation and a lens that leaves a blurred retinal image should be avoided. The choice of IOL power should be individualised based on the child's need and refractive status of the other eye in unilateral cases.<sup>4</sup>

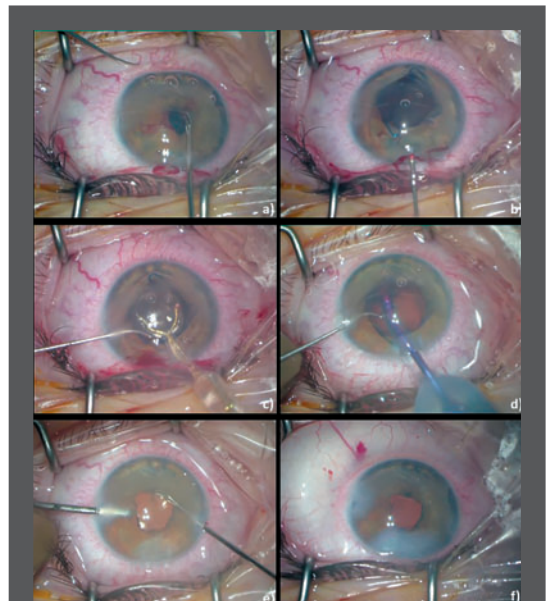
In recent years, acrylic IOLs have gained popularity over polymethyl methacrylate (PMMA) IOLs, which were the IOL of choice for many years.<sup>5-7</sup> In children, hydrophobic acrylic IOLs are preferred because of greater biocompatibility and a smaller incision size with use of the foldable design, plus there is late-onset and a lower rate of PCO formation. These IOLs are used by 93% of paediatric cataract surgeons.<sup>4</sup> In children with uveitic cataracts, decreased postoperative inflammation has been reported with the use of heparin-surface-coated PMMA IOLs.<sup>8</sup>

I targeted this case as slightly hyperopic matching the refraction of the fellow eye. The IOL used was IC-8 (AcuFocus) with a power of +27.5 D, and a target refraction of +1.32 D, using the Hoffer Q formula. I had to use an iris hook to very gently open up the iris due to posterior synechia and pupil dysgenesis. Micro forceps had to be used through different side ports. A 23-gauge (23g) Seibel Capsulorhexis Forceps (Figure 1) was used for opening of the capsule in the shallow anterior chamber. This instrument is designed to minimise OVD loss to maintain stable anterior chamber, as well as provide greater visibility and control of capsulorhexis, especially in eyes with a shallow anterior chamber. As the shaft is stable, the branches can be moved to allow optimal control over the capsulorhexis.

Surgery was successful. Post-operative results are shown in Table 1. At the 12-week postop visit, manifest refraction was measured as +4.00/-3.00 × 43, with a corrected VA of 0.15 logMAR at distance and 0.1 logMAR at near. With the last visit in October 2018, the patient and his parents remain very satisfied with the results, and refraction has decreased to +3.00/-2.50 × 52 and a corrected VA of 0.2 logMAR at distance. This case was in 2016. Follow-up is 18 months.

**Case 2: uveitic patient with cataract**

Another boy presented with unilateral



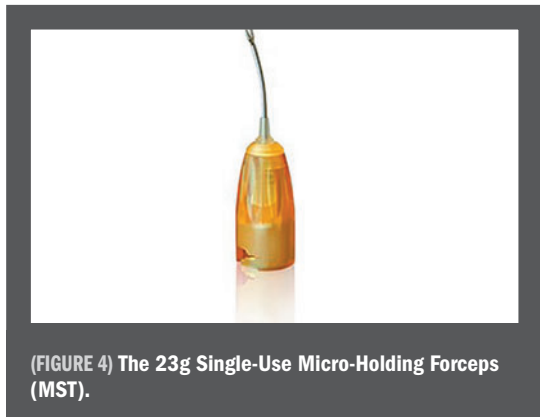**(FIGURE 2) Cataract surgery in uveitic paediatric patient. (Images courtesy of Dr Kretz)**



**(FIGURE 3) The 23g Single-Use Hoffman/Ahmed Horizontal Curved Scissors (MST).**

congenital cataract at 5 years old. Again, he had been turned away from a clinic and a university for treatment. He had uveitis with pupillary membrane; the whole pupil was clogged with a dense fibrin membrane. His vision was decreased to hand movements from 0.5 logMAR over the last 24 months.

During surgery (Figure 2), I used the 23g Hoffman/Ahmed Horizontal Curved Scissors (Figure 3) to cut out the pupillary membrane and inserted a Malyugin Ring 2.0 (MST), which



**(FIGURE 4) The 23g Single-Use Micro-Holding Forceps (MST).**

was easy to use, expanding the pupil up to 6 mm and protecting the iris from damage.<sup>9</sup> I proceeded with the irrigation port and performed the anterior capsulotomy with the Zepto capsulotomy system (Mynosys) to open the lens capsule and perform the cataract surgery. The CT Lucia 211P IOL (Carl Zeiss Meditec) with a power of +28 D was implanted, with a target refraction of +0.35 D using Barrett formula. I chose this IOL as it is a hydrophobic acrylic IOL with imbedded heparin surface coating to prevent further inflammation.

With the Zepto capsulotomy system, an element surrounded by a silicone plastic shell is attached to a suction tube and introduced into the eye via a tiny (2.2–2.4 mm) incision. The silicone shell squeezes down and there is a push rod inside the silicone sleeve used to expand the ring to a circle, and nitinol retains it back to a circle. Pulling the push rod out, you retract it and turn on the suction and the whole thing sucks itself down onto the anterior capsule.<sup>10</sup> The Zepto system is fast and easy to use, and offers a very precise capsulotomy opening with higher stability compared to manual capsulotomy.

In the anterior chamber, I carefully grabbed the pupillary membrane in the centre and lifted it. Then I made a hole at the iris membrane margin, filled viscoelastic behind the pupillary membrane and went in with the instrument to loosen any deposits

(synechiae) behind the membrane, then filled it up again with viscoelastic so the membrane comes up in the anterior chamber. From the left side port, I entered again with the 23g Micro-Holding Forceps (Figure 4), lifted up the membrane and on the other side I came in with the 23g Hoffman/Ahmed Horizontal Curved Scissors, which are exchangeable. When dealing with complex cases, I find it much easier to use the MST handle, which is compatible with all exchangeable single-use heads that can be opened from the packaging when needed.

With the exchangeable 360 handle (MST), you can turn the direction of the instrument, so I was able to cut around the whole pupil just by turning the scissors in the right direction. This allowed flexibility and ease of use intra-procedure. The development of fine 23.25g instruments, especially the scissors and forceps, helps in chamber stability.<sup>11</sup>

At 1 day postop, uncorrected vision was measured as 0.5 logMAR. At postoperative day 4, best corrected visual acuity was 0.2 logMAR. The child has chronic uveitis, for which he is prescribed topical steroid treatment, but overall his vision, and therefore quality of life, has vastly improved. At 3 months postop, the uveitis is under control with topical dexamethasone drops, uncorrected visual acuity is 0.4 logMAR, which is improved to 0.2 logMAR with correction. The child's mother is very happy with the surgical outcomes.

Possible complications or risks postoperatively include glaucoma, retinal detachment, infection and the need for more surgeries. In my opinion the use of single-use instruments may have the potential to reduce some of these risks, especially in paediatric cases.

### Discussion

Both cases are similar in that both were very small eyes. Paediatric cataract surgery is a challenge as the eyes are small and there is less space

to manoeuvre. This is where very precise fine instruments are required to access the anterior chamber. For instance, in cases with uveitis with pupillary membrane, you need a forceps intra-procedure to hold the membrane on one side and then the curved scissors in the other hand to open the membrane. It is easy to turn the scissor head instead of having to turn the whole instrument in your hand.

### Instruments

Such paediatric cases with a complete membrane in the pupil area are rare and, therefore, I do not hold a set of re-usable surgical instruments and used a disposable set in both cases. Disposable instruments are certain to be sterile and scissors to have a sharp blade, plus single-use forceps will hold tight and not be damaged. Being able to easily exchange just the head of the instruments is ideal.

I find the MST single-use instruments of similar quality to non-disposable ones. In fact, there is a higher risk of damage with traditional ones as they are frequently re-sterilised and handled more often.

With a wider selection of disposable tips for micro-instruments available, there is a greater choice. It also helps to know you can carry out what you are planning with the new instruments; using single-use promises they will not be broken or damaged from re-use. So, I find disposable more practical and safer.

**OTE** For references go to Europe.  
[OphthalmologyTimes.com/Kretz](http://OphthalmologyTimes.com/Kretz)

**DR FLORIAN T. A. KRETZ, MD, FEBO**

**E:** [F.Kretz@augenklinik.de](mailto:F.Kretz@augenklinik.de)

**Institution:** Augentagesklinik Rheine, Osnabrücker Straße 233-235, Rheine, NRW 48429, Germany.

# BEAT YOUR PERSONAL BEST. FAST. PRECISE. RELIABLE.



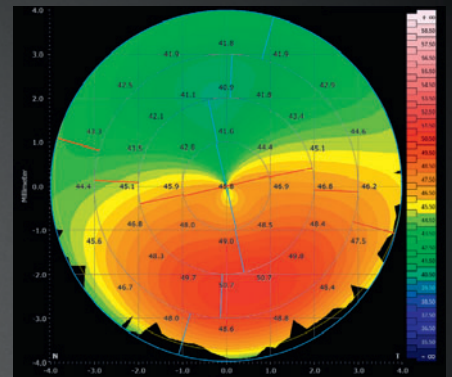
**Jan Frodeno**  
Triathlon Olympic Champion  
Double IRONMAN World Champion

## ANTERION®

**ANTERION** is the multimodal imaging platform optimized for the **anterior segment**.

With the **Cornea App** you can quickly visualize your patient's corneal geometry, precisely diagnose corneal alterations and enhance your surgical planning.

Take the lead with corneal tomography and wavefront analysis based on **swept-source OCT, all in one device**.



Keratoconus: Total corneal power map.

200429-001 INT-AE19©Heidelberg Engineering GmbH



**CORNEA**



**CATARACT**



**METRICS**

[www.anterion.com/cornea](http://www.anterion.com/cornea)

**HEIDELBERG  
ENGINEERING**

## ETM valuable in surgical planning and evaluation of outcomes

Measurements indicate the corneal epithelium plays a crucial role in outcomes

By **Dr Arun C. Gulani**  
and **Dr Aaisha A. Gulani**

For many years, I have been travelling the world teaching surgeons about Corneoplastique—my philosophy and practice whereby any eye with visual potential can attain 20/20 or better unaided vision with individualised use of the entire range of ocular surface, corneal, and intraocular techniques.<sup>1</sup>

This approach focuses on the refractive endpoint of unaided emmetropia and considers the spectrum of available techniques in a holistic way to prepare and repair the eye. As a result, virgin eyes with refractive error can achieve vision beyond 20/20, and nearly any post-surgical problem can be repaired to 20/20.

In addition, non-candidates—for reasons including corneal scar, thin cornea, ectasia and irregular astigmatism—can be converted to candidates.



Dr A. C. Gulani



Dr A. A. Gulani

### Adding epithelial thickness mapping

A recent addition to this approach is epithelial thickness mapping (ETM). ETM—an anterior segment optical coherence tomography (AS-OCT) mode available with certain OCT technology (iVue, iFusion, and Avanti, all from Optovue)—is the only FDA-approved, non-contact method of quantitatively measuring the corneal epithelium and stroma.

With a large 9-mm scan, it maps epithelial patterns and irregularities that are associated with subclinical keratoconus and ectasia risk,<sup>2</sup> dry eye disease<sup>3</sup> and previous refractive surgery.<sup>4,5</sup>

As such, ETM is a valuable tool for pre-surgery risk evaluation, surgical planning, evaluation of outcomes and enhancement procedure planning.

I have long suspected that the epithelium plays a significant role in quality of vision and refractive surgery outcomes. ETM enables me to document this.<sup>6</sup>

To further elucidate the role of the epithelium, I am mapping epithelial thickness before and after the Corneoplastique procedures.

ETM repeatedly indicates a strong correlation between vision and the smoothness of the epithelium.

The epithelium appears to smooth the anterior cornea and maximise the interplay of the eye's optical

components despite underlying irregular stroma.

I believe this helps to explain the successful results I've achieved over three decades using the least-invasive procedures to provide patients with life-changing quality of vision.<sup>7</sup>

Consider, for example, the following cases.

### Case 1: unaided 20/25 vision for eye with central corneal herpetic scar in only seeing eye

Based on multiple consultations with other surgeons, a 42-year-old male with a central corneal herpetic scar and 20/400 vision in his only seeing eye expected to require a corneal transplant to obtain usable vision.

Instead, given that his vision in that eye was correctable to 20/50, after a detailed informed consent, he elected to proceed with laser Corneoplastique (epithelium removal and modified excimer laser application) to refractively reshape the scar without treating the underlying cornea.

Despite the presence of residual scar, and no improvement in astigmatism, the patient's postoperative unaided vision is 20/25.

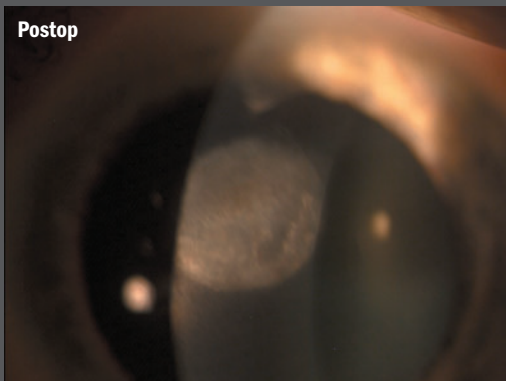
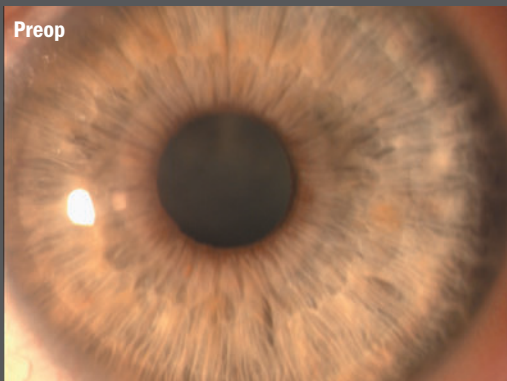ETM shows how the epithelium remodelled over the residual scar, essentially filling in the irregular area to smooth the anterior corneal surface.

Note that treating this eye based on corneal topography would have resulted in a misdirected treatment target. Topography was not a factor in light of the epithelial changes that occurred and the most important measure of success, which is the patient's final vision outcome and perceived improvement.

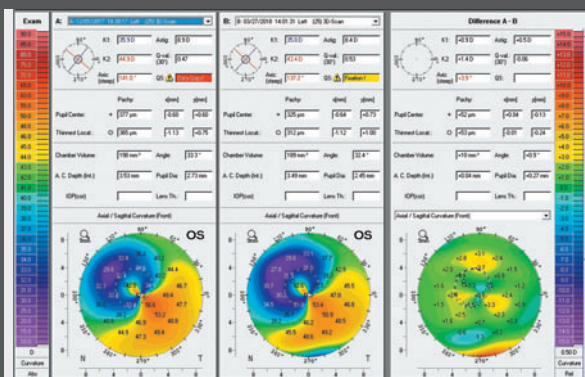
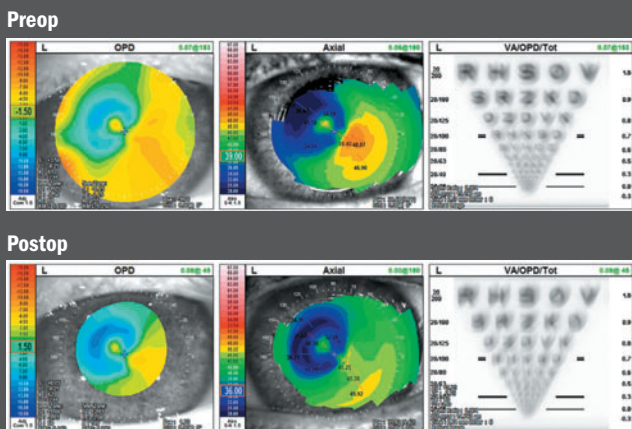
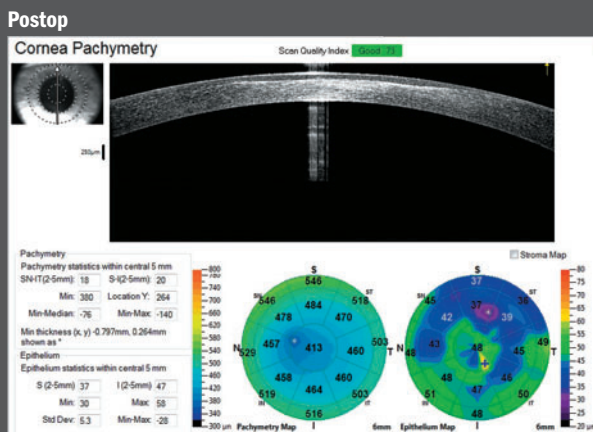
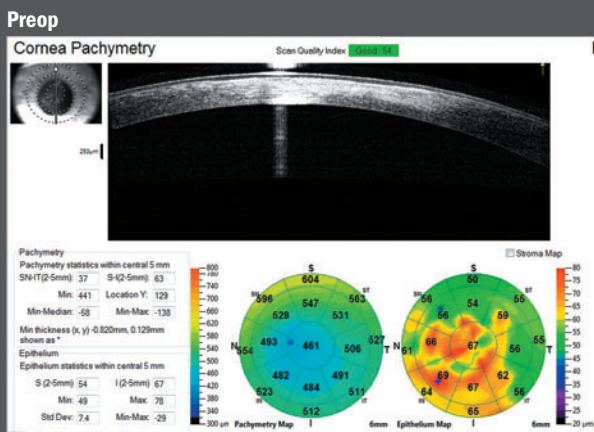
### IN SHORT

► **Drs Arun C. Gulani and Aaisha A. Gulani share how epithelial-based refractive surgery can achieve unprecedented vision results with the least-invasive procedures in even the most complex cases.**

CASE 1



Left. A 42-year-old male with a central corneal herpetic scar and 20/400 vision in his only seeing eye. Right. The patient's postoperative unaided vision is 20/25.



ETM shows how the epithelium remodelled over the residual scar, essentially filling in the irregular area to smooth the anterior corneal surface.

Case 2: unaided 20/10 vision for a previous contact lens wearer

Based on a thin cornea, high-myopic astigmatism and predisposition for

dry eye, I recommended advanced surface ablation for this 34-year-old female who desired freedom from contact lenses.

Her postoperative unaided visual

acuity is 20/10. She reports 10/10 satisfaction with the improvement, especially with night vision, which, she notes, is much better than her previous night vision with contact lenses.

# Effective presbyopia correction using an EDoF IOL in a patient with AMD

Dr. Ekkehard Fabian, MD

He received his medical degree from the Technical University of Munich in 1984, specializing in Ophthalmology. His research interests lie within the fields of cataract, glaucoma and refractive excimer-laser surgery as well as quality management in ophthalmology.

## CASE HISTORY

A 68-year-old female patient presented on referral for cataract surgery. She stated that she actively participates in sports and would like to be able to see well without glasses.

A refraction performed in 1998 showed she had +0.5 D of sphere in both eyes. In 2018, her refraction was -0.50 -2.25 x 10° (Vcc<sub>Distance</sub>=0,5) add +2.50 (Vcc<sub>Near</sub>=0,5) OD; +2,00 -1.00 x 127° (Vcc<sub>Distance</sub>=0,8) add +2.50 (Vcc<sub>Near</sub>=0,8) OS. The prescription in her glasses was: +1.25 -0.75 x 10° Vcc=0.2 OD; +1.50 -1.25 x 175° Vcc=0.63. Near: +3.75 -0.50 x 8° OD; +3.25 -0.50 x 156° OS.

In addition to refraction and visual acuity, the patient underwent a comprehensive ophthalmic examination that included Scheimpflug camera imaging (Pentacam HD, Oculus), fundus imaging with a non-mydriatic color fundus camera (VISUCAM PRO NM, Carl Zeiss Meditec), and optical biometry with swept-source OCT (IOLMaster 700, Carl Zeiss Meditec). Multiple macular drusen were present in both eyes and were worse in the right eye. The patient had no vision defects on Amsler grid testing and no other remarkable findings. Based on this, together with the patient the decision was made, to not implant a trifocal IOL but an Extended Depth of Focus (EDoF) IOL (ZEISS AT LARA) instead.

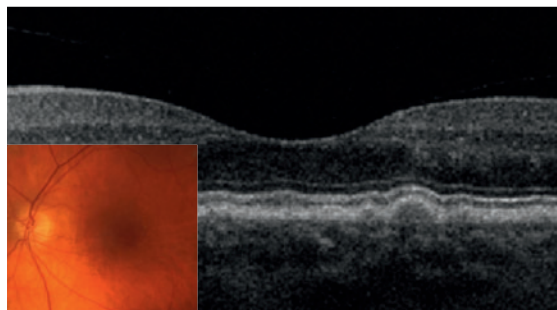


Fig. 1 Fundus imaging with VISUCAM PRO NM show multiple macular drusen.

Biometric data and IOL power calculations obtained using the IOLMaster 700 are listed below.

OD: K1 42.62 D/7.79 mm; K2 42.89 D/7.74 mm; cylinder -0.30D @ 175°; anterior chamber depth 3.31 mm; axial length 23.44 mm; IOL power for emmetropia 21.50 D  
 OS: K1 43.34 D/7.66 mm; K2 43.51 D/7.63 mm; cylin-

der -0.19 D @ 123°; anterior chamber depth 3.29 mm; axial length 23.35 D; IOL power for emmetropia 21.00;

## SURGERY

The patient underwent bilateral implantation with the extended depth of focus (EDoF) AT LARA 829MP IOLs (Carl Zeiss Meditec) using a micromonovision approach. The right eye was operated first with implantation of a 21.5 D lens to achieve a slightly myopic target of -0.47 D and a 20.5 D IOL was implanted OS targeting near emmetropia (calculated -0.17 D).

The surgery was performed through a 2.2 mm incision with conventional phacoemulsification. Preoperative data acquired with the IOLMaster 700 were transferred to the OPMI LUMERA 700 microscope (Carl Zeiss Meditec) and used with the CALLISTO eye ASSISTANCE markerless system (Carl Zeiss Meditec) to guide accurate centration and sizing of the capsulorhexis. Careful attention was directed to meticulous polishing of the anterior capsule to limit fibrosis and opacification that could affect the refractive and functional outcomes.

## OUTCOMES

Images taken with the CALLISTO eye at follow-up 1 week after surgery show that the IOLs are well-centred. At 6 weeks after surgery, binocular uncorrected VA (decimal) was 0.9 at distance and 0.8 at both intermediate and near. Binocular corrected DVA was 1.0.

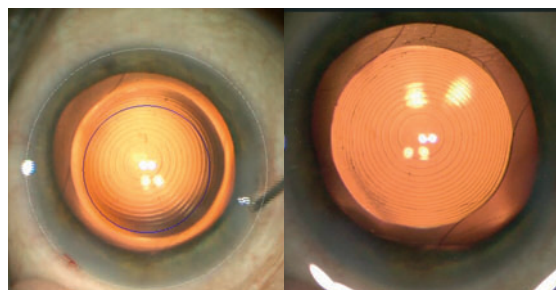


Fig 2: Images taken with the CALLISTO eye at follow-up 1 week after surgery.

The patient was asked to give feedback about the implants in a patient questionnaire, taken 8 weeks after surgery. She completed the questionnaire without requiring glasses to read or write. The report proves a very high patient satisfaction and states that she does not need

glasses for distance and intermediate and only seldomly for near vision.

## DISCUSSION

The trifocal AT LISA tri 839MP and AT LISA tri toric 939MP IOLs are my IOLs of choice for patients interested in achieving spectacle independence after cataract surgery. My clinical experience with these IOLs over the last 6 to 7 years is consistent with results from published studies showing that they provide good image quality with a full range of functional uncorrected vision.<sup>1-3</sup>

Nevertheless, reduced contrast sensitivity and potential for nighttime dysphotopsias remain inherent issues with all diffractive multifocal IOLs.<sup>4</sup> Therefore, patients who have ocular conditions that are associated with reduced contrast sensitivity, such as glaucoma or age-related macular degeneration, as well as patients who may be intolerant of nighttime dysphotopsias, should not be implanted with a trifocal IOL.

Compared with multifocal IOLs, the AT LARA EDoF IOLs have less effect on contrast sensitivity and cause less problems with nighttime dysphotopsias.<sup>4</sup> Designed with spherical and chromatic aberration correction and smooth phase zones, the AT LARA IOLs deliver excellent distance and intermediate vision, optimise contrast sensitivity, and minimise light scattering and the risk for debilitating nighttime visual disturbances. Having a wide range of focus, the AT LARA IOLs can also provide patients with functional near vision. Use of a micromonovision approach, which targets the dominant eye for distance and the nondominant eye for reading, can meet the needs of patients wanting better near vision.

The AT LARA is also available in a toric version, and that is important considering that approximately one-third of cataract patients may need astigmatism correction to achieve good uncorrected vision with presbyopia-correcting IOL technology. Intraoperative image guidance with the CALLISTO eye improves the accuracy of toric IOL alignment compared with manual marking techniques.<sup>5</sup> Even in non-toric cases, the CALLISTO eye has value for guiding capsulorhexis and accurate IOL centration that is important for optimal vision.

The patient in this case was eager to see well without glasses after her cataract surgery. Bilateral implantation of a monofocal IOL with a monovision approach is another strategy for providing patients with reduced spectacle dependence after cataract surgery. This option can result in satisfactory outcomes and avoid the issues of reduced contrast sensitivity and dysphotopsias accompanying multifocal IOL technology. However, compared with bilateral implantation of the AT LARA EDoF IOLs using a micromonovision approach, it is more likely to result in poorer uncorrected distance VA and reduced depth perception.

All presbyopia-correcting IOLs have some limitations. Achieving success and patient satisfaction with use of these technologies depends on performing a comprehensive diagnostic examination preoperatively to evaluate ocular health and determine whether patients are appropriate candidates for implantation. With its swept-source OCT, the IOLMaster 700 may detect macular pathologies.<sup>6</sup> The VISUCAMPRO NM is a user- and patient-friendly device for definitive diagnosis of retinal disease and was valuable in this case for confirming the presence of macular drusen.

A careful history is also needed to understand each patient's vision needs, and detailed counseling is mandatory so that patients understand the pros and cons of the presbyopia-correcting surgical options and have appropriate outcomes expectations. When discussing presbyopia-correcting implants, I avoid referring to them as "premium IOLs". Instead I present these lenses as advanced technologies and describe their additional functions because I feel this approach helps patients understand and accept the extra fees that are charged for presbyopia-correcting IOL surgery. Patients who choose advanced technology IOLs are also asked to sign a waiver form acknowledging that they were informed of the risks and benefits.

## CONCLUSION

Because I have accumulated several years of excellent experience and results with the AT LISA tri family of IOLs, they remain my first choice for presbyopia-correcting IOL surgery. The AT LARA IOLs are a newer addition to our presbyopia-correcting IOL armamentarium and have also been associated with excellent outcomes in my practice. From my perspective, the AT LARA IOLs are a perfect complement to the family of AT LISA tri IOLs and an important option that broadens the population of patients who can be offered the benefit of reduced spectacle dependence after cataract surgery.

**Dr. Ekkehard Fabian, MD**  
Medical Director & Professor at the  
Eye Center MVZ Rosenheim Inntal  
In Rosenheim, Germany

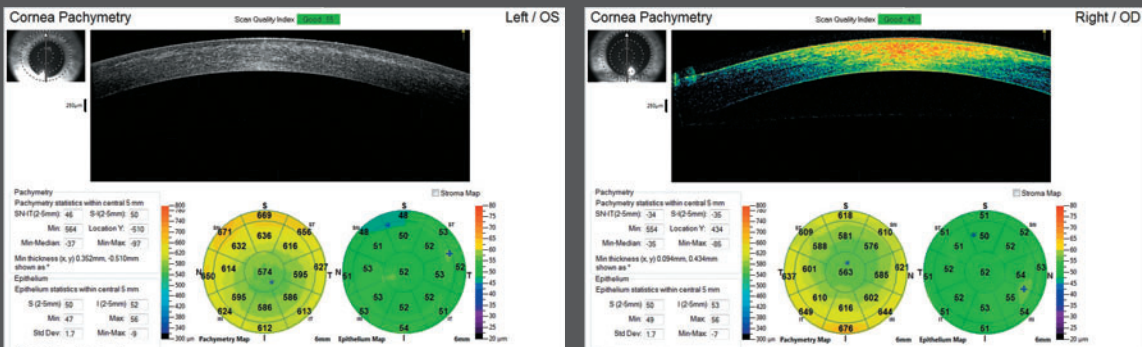


## References

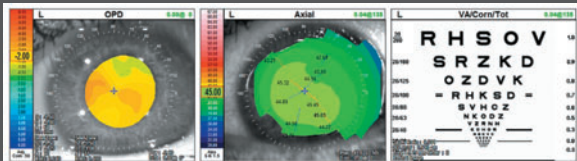
- Mencucci R, Favuzza E, Caporossi O, Rizzo S. Visual performance, reading ability and patient satisfaction after implantation of a diffractive trifocal intraocular lens. *Clin Ophthalmol*. 2017;11:1987-1993.
- Mojzic P, Majerova K, Hrcokova L, Piñero DP. Implantation of a diffractive trifocal intraocular lens: one-year follow-up. *J Cataract Refract Surg*. 2015;41(8):1623-16230.
- Kretz FT, Breyer D, Diakonis VF, et al. Clinical outcomes after binocular implantation of a new trifocal diffractive intraocular lens. *J Ophthalmol*. 2015;2015:962891.
- Akella SS, Juthani VV. Extended depth of focus intraocular lenses for presbyopia. *Curr Opin Ophthalmol*. 2018;29(4):318-322.
- Mayer WJ, Kreutzer T, Dirisamer M, et al. Comparison of visual outcomes, alignment accuracy, and surgical time between 2 methods of corneal marking for toric intraocular lens implantation. *J Cataract Refract Surg*. 2017;43(10):1281-1286.
- Hirschall N, Leisser C, Radda S, Maedel S, Findl O. Macular disease detection with a swept-source optical coherence tomography-based biometry device in patients scheduled for cataract surgery. *J Cataract Refract Surg*. 2016;42(4):530-536.

# (cataract & refractive)

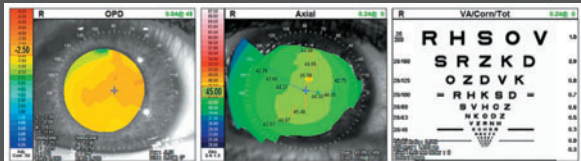
## CASE 2



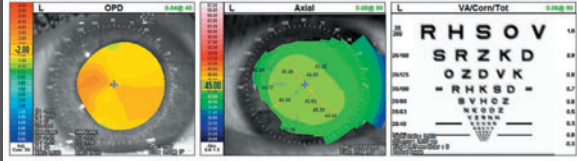
### Preop



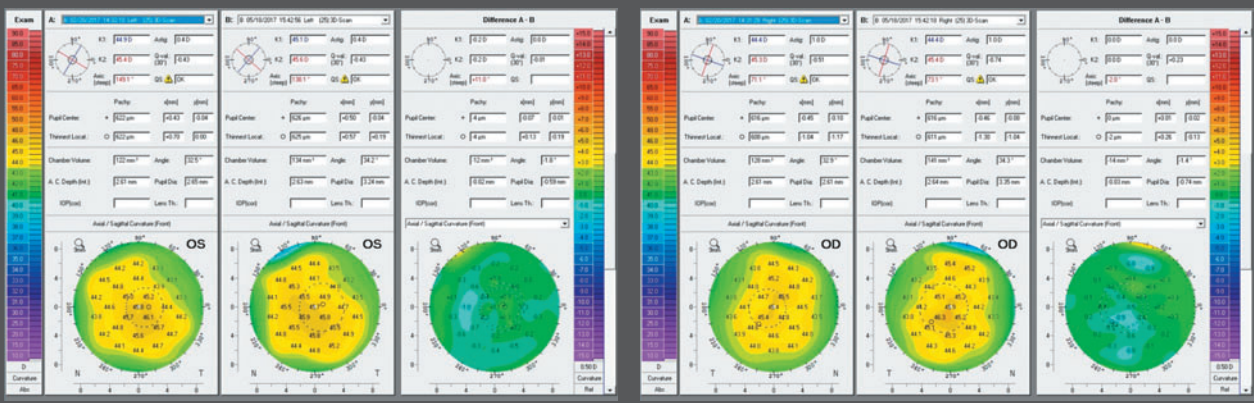
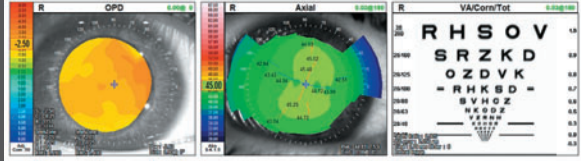
### Preop



### Postop



### Postop



Unaided 20/10 vision for a previous contact lens wearer. ETM of both eyes shows a regular contour of the epithelium, an indication of the importance of the epithelium in achievement of pristine vision.

ETM of both eyes shows a regular contour of the epithelium, an indication of the importance of the epithelium in achievement of pristine vision.

### Case 3: unaided 20/30 vision for eye with posterior corneal scars

Forceps trauma suffered at birth caused a posterior Descemet's tear and

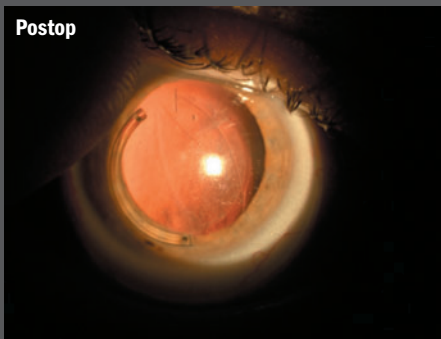
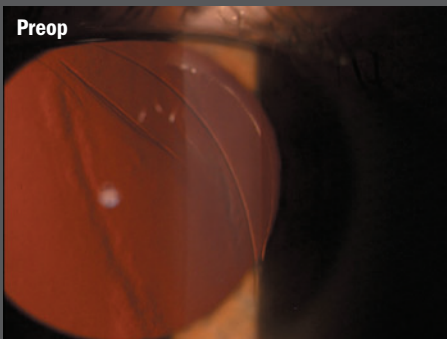
posterior corneal scars in the right eye of this 23-year-old male. His cornea was ectatic, he had 5.2 D of irregular astigmatism and visual acuity of 20/400, which was correctable to 20/50.

Rather than perform a lamellar transplant to stabilise the cornea and improve its shape, I placed corneal inserts (Intacs, Addition Technology) with careful selection of incision axis.

The result was a nearly 4 D reduction in astigmatism and unaided 20/30 vision. ETM shows a higher anterior regularity, apparently a compensatory mechanism for overriding the posterior corneal irregularity, which is the likely explanation for the patient's subjective and objective vision improvement and extreme satisfaction.



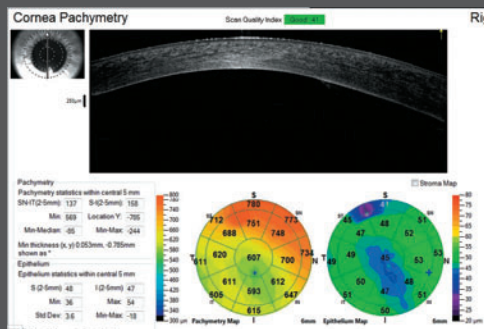
**CASE 3**



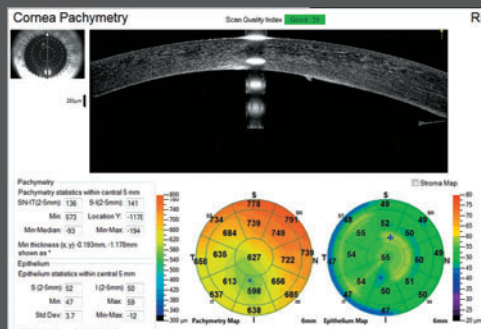
**Left.** Forceps trauma suffered at birth caused a posterior Descemet's tear and posterior corneal scars in the right eye of this 23-year-old male. His cornea was ectatic, he had 5.2 D of irregular astigmatism and visual acuity of 20/400, which was correctable to 20/50.

**Right.** Rather than perform a lamellar transplant to stabilise the cornea and improve its shape, corneal inserts were placed with careful selection of incision axis.

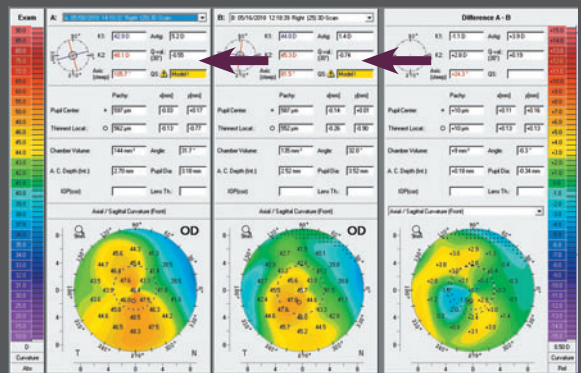
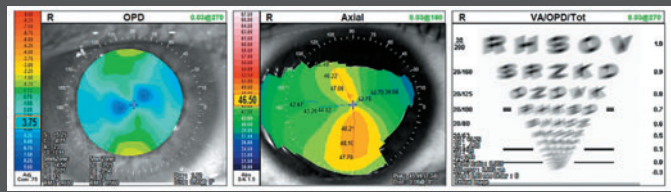
**Preop**



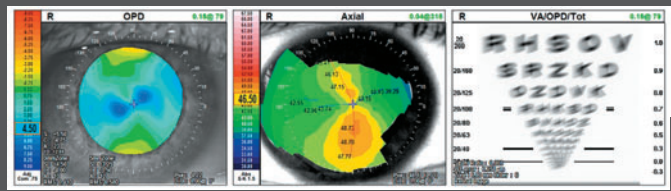
**Postop**



**Preop**



**Postop**



The result was a nearly 4 D reduction in astigmatism (arrows) and unaided 20/30 vision. ETM shows a higher anterior regularity, apparently a compensatory mechanism for overriding the posterior corneal irregularity, which is the likely explanation for the patient's subjective and objective vision improvement and extreme satisfaction.

**Case 4: unaided 20/20 vision with laser following failed Intacs**

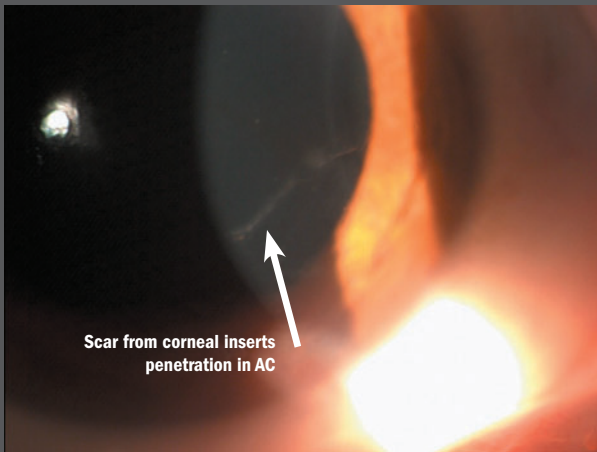
A 47-year-old female was referred to me after Intacs placed by her surgeon to address keratoconus in the right eye extruded into the anterior chamber. The surgeon extracted the corneal inserts, which caused a scar.

The previous surgeon had also performed corneal crosslinking, which stabilised the cornea and allowed me to reshape it with laser Corneoplastique (the eye was refractable to 20/25) without disturbing the previous surgery. The outcome of the laser procedure is unaided 20/20 vision despite

lack of change in astigmatism on topography.

Postoperative ETM shows epithelium remodelling to fill in not only the refractively induced corneal curvature but also the area of the scar and the uneven stromal thickness that is the hallmark of the keratoconus itself.

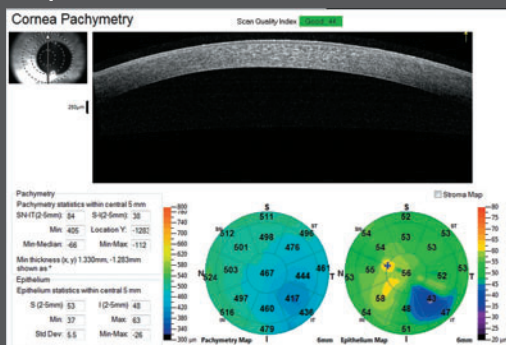
CASE 4



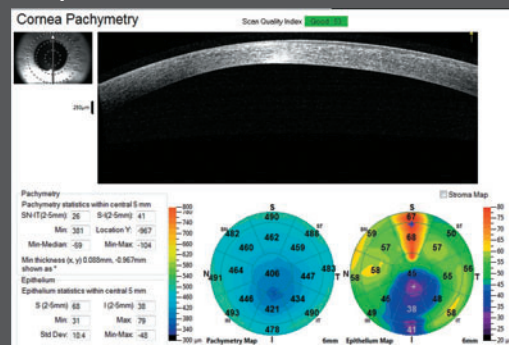
A 47-year-old female was referred after corneal inserts placed by her surgeon to address keratoconus in the right eye extruded into the anterior chamber. The surgeon extracted the corneal inserts, which caused a scar.

The outcome of the laser procedure is unaided 20/20 vision despite lack of change in astigmatism on topography.

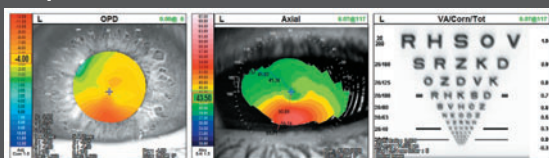
Preop



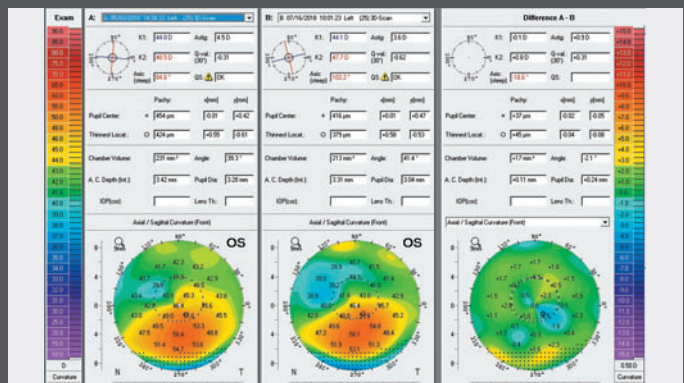
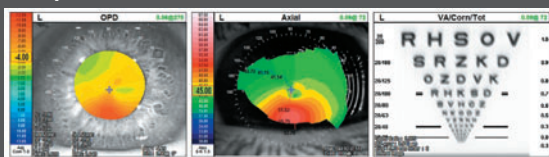
Postop



Preop



Postop



Postoperative ETM shows epithelium remodelling to fill in not only the refractively induced corneal curvature but also the area of the scar and the uneven stromal thickness that is the hallmark of the keratoconus itself. (Images courtesy of Dr Arun C. Gulani)

### Seeing the whole picture

Now is a good time for refractive surgeons to begin using ETM to understand the role of the epithelium in each case.

Understanding the different patterns and changes in the epithelium and how they impact vision will move the field toward better outcomes, much like what occurred with the emergence of topography many years ago.

With my work involving Corneoplastique and ETM, I aim to confirm that epithelial-based refractive surgery can allow surgeons to achieve unprecedented vision results with the least-invasive procedures in even the most complex cases.

Looking beyond corneal shape to another dominant impact factor in keratorefractive surgery, my

practice is continuing to collect images and data from cases across the spectrum of refractive procedures and complications referred to us in order to potentially prepare a next-generation atlas.

The epithelium—seen in the past as the mole hill in the realm of vision correction—may be the mountain.

### REFERENCES

1. Gulani AC. Corneoplastique: Art of vision surgery. *Indian J Ophthalmol.* 2014; 62:3-11.
2. Li Y, Chamberlain W, Tan O, Brass R, Weiss JL, Huang D. Subclinical keratoconus detection by pattern analysis of corneal and epithelial thickness maps with optical coherence tomography. *J Cataract Refract Surg.* 2016;42:284-295.
3. Kanellopoulos AJ, Asimellis G. In vivo 3-dimensional corneal epithelial thickness mapping as an indicator of dry eye: preliminary clinical assessment. *Amer J Ophthalmol.* 2014;157:63-68.
4. Kanellopoulos AJ, Georgiadou S, Asimellis

G. Objective evaluation of planned versus achieved stromal thickness reduction in myopic femtosecond laser-assisted LASIK. *J Refract Surg.* 2015;31:628-632.

5. Tang M, Li Y, Huang D. Corneal epithelial remodeling after LASIK measured by Fourier-domain optical coherence tomography. *J Ophthalmol.* 2015;2015:860313.
6. Gulani AC. Irregular astigmatism to 20/20. Presentation at the International Refractive Surgery Congress, Shanghai, China, May 2018.
7. Gulani AC. Corneal re-shaping for irregular astigmatism: back to 20/20. Presentation at the Advanced Refractive Congress, Ft Lauderdale, FL, July 2018.

### DR ARUN C. GULANI, MD, MS

E: [gulanivision@aol.com](mailto:gulanivision@aol.com)

Dr Gulani, an anterior segment specialist and creator of the Corneoplastique concept of vision correction, is the founder of Gulani Vision Institute in Jacksonville, FL, USA.

### DR AAISHA A. GULANI, BS

Dr Gulani is a senior at the University of Pennsylvania where she's concentrating on healthcare management and finance at the Wharton School of Business.



Paris  
May 11-14, 2019

## 125th International Congress of the French Society of Ophthalmology

Report SFO: "OCT in ophthalmology" by Dr Jean-François KROBELNIK  
Second rapport of the SFO: "Myopia" by Dr David GAUCHER and Dr Nicolas LEVEZIEL

### Roundtables:

- Structural analysis in glaucoma.
- Imaging and functional exploration in neuro-ophthalmology.
- Implantation in cataract surgery.
- Scleritis and episcleritis.
- Pachychoroidopathy: screening and treatment.
- Inflammatory orbital tumors.
- Maxillofacial and Rheumatology.

NEWS IN teaching and innovations: Cornea - Uveitis  
European Board of Ophthalmology  
More than 100 exhibitors and many symposia

### Surgery SFO2019

#### Guest lectures:

- Retinal blindness in children. E. Traboulsi
  - OCT-A: tips and tricks. D. Chow
  - AI in ophthalmology. D. Azar
  - DMEK and Bowman layer transplantation. G.R. Melles
- Symposia:** West Africa – Brazil – European – Lebanon – North Africa – EBO
- Focus:** Difficult Refraction – Artificial Intelligence – Stem Cells and Gene Therapy
- Annual meetings:**  
Clinical cases of cornea, glaucoma, retina and low vision

The program will be available on [www.sfo.asso.fr](http://www.sfo.asso.fr) and "SFO 2019" app  
Information and registration on [www.sfo.asso.fr](http://www.sfo.asso.fr)

# Nitric-oxide-donating drugs: significant IOP lowering with once-daily dosing

Advantages of nitric-oxide-donating drugs compared with timolol

By **Lynda Charters;**

Reviewed by  
Dr Gail F. Schwartz



Dr Schwartz

In the quest to provide more options to patients with glaucoma, the nitric oxide (NO)-donating drugs can provide significant reductions in intraocular pressure (IOP) associated with open-angle glaucoma (OAG) and ocular hypertension (OHT) in clinical and experimental settings when compared with timolol.

NO offers a few advantages, in that it can diffuse across cellular membranes and is a potent vasodilator. In addition, it is synthesised endogenously by L-arginine via NO synthase (NOS), which then generates NO, and it activates soluble guanylyl cyclase, which results in upregulation of cyclic guanosine monophosphate that serves as a second messenger.

**‘In the eye, [nitric oxide] causes the trabecular meshwork to relax, regulates the permeability of Schlemm’s canal and causes vasodilation of the ocular blood vessels.’ - Dr Schwartz**

In the eye, NO causes the trabecular meshwork to relax, regulates the permeability of Schlemm’s canal and causes vasodilation of the ocular blood vessels. In addition, research has shown that dysfunction of the NO-guanylyl-cyclase pathway is associated with an increased incidence of glaucoma, according to Gail Schwartz, MD, which provides insight into the drug’s mechanism of action.

## How NO works

In normal eyes, she explained, NO is involved with IOP homeostasis. The conventional pathway in the eye, i.e. the trabecular meshwork and Schlemm’s canal, is IOP sensitive, in contrast to the uveoscleral pathway. With increases in IOP,

the cells in Schlemm’s canal are affected by pressure and ultimately collapse; this is the same stress to which vasoconstricted blood vessels are subjected. When the IOP increases, endothelial NOS (eNOS) is produced and increases the supply of NO that, in turn, relaxes the trabecular meshwork and Schlemm’s canal and increases the permeability of the trabecular meshwork and improves aqueous outflow.

**‘A boon for patients is its [latanoprostene bunod’s] once-daily dosing.’ - Dr Schwartz**

## NO in glaucoma

In contrast to the fine-tuned outflow process in normal eyes, in glaucomatous eyes, the IOP homeostasis that depends on NO is disrupted in a few ways. “eNOS expression is decreased in the ciliary muscle, trabecular meshwork and Schlemm’s canal. The levels of NO in the aqueous humor are decreased. Genetic variations in eNOS have been associated with primary open-angle glaucoma [POAG],” Dr Schwartz, who is in a private glaucoma practice and assistant professor, Wilmer Eye Institute, Baltimore, explained.

When treating glaucoma, systemically administered nitroglycerin reduces the IOP in OAG, but not in closed-angle glaucoma because the NO cannot reach the trabecular meshwork, which eliminates the incremental benefit of latanoprost (Xalatan, Pfizer) when it is administered alone. When administered

## IN SHORT

▶ **Nitric-oxide-donating drugs can provide significant reductions in intraocular pressure (IOP) associated with open-angle glaucoma and ocular hypertension compared with timolol.**

topically, nitroglycerin has been shown to reduce IOP in primates; increased dietary intake of nitrate contained in green leafy vegetables can lower the risk for POAG.

Latanoprostene bunod (LBN) 0.024% (Vyzulta, Bausch + Lomb) is the only commercially available NO-donating drug. LBN works when it is broken down by corneal esterases into latanoprost acid and butanediol mononitrate, the latter of which then breaks down into 1,4-butanediol and NO, Dr Schwartz said.

### The NO effect

The action of LBN raises the question about which component of the drug has the positive effect on the IOP—the latanoprost or NO? Dr Schwartz explained that LBN relaxes trabecular meshwork cells *in vitro*, which latanoprost does not. LBN lowers the IOP in both prostaglandin FP receptor knockout mice and prostaglandin-non-receptor rabbits, which latanoprost also does not. “Higher concentrations of latanoprost over 0.005% do not lower IOP better than lower concentrations possibly because of saturation of the FP receptors,” she noted.

### Clinical trials

The phase 2 VOYAGER 28-day dosing study compared LBN 0.024% with latanoprost 0.005% in patients with OAG and OHT. The study showed maximal IOP lowering with LBN 0.024% and 0.040%. “LBN significantly reduced IOP by 2 mm Hg or more in 45% of patients compared with latanoprost 0.005% alone. A greater proportion of patients taking LBN had an IOP below 18 mm Hg at all visits compared with latanoprost,” she said.

The phase 2, sleep lab crossover Constellation Study included patients with OAG and OHT with a baseline IOP over 22 mm Hg. The researchers reported that LBN improved the ocular perfusion pressure compared with timolol (nocturnal) and baseline ( $P = 0.01$  and  $P < 0.006$ , respectively). LBN also significantly ( $P = 0.004$ ) reduced the nocturnal

latanoprost (hyperemia, ocular irritation, eye pain, and pain at the installation site).

### In the pipeline

Nipradilol, a NO-donating beta-blocker, is being studied in Japan and is reported to be comparable to timolol 0.5%.

Two other NO-donating drugs

‘Nitric oxide donors are a new and safe addition to our glaucoma drug armamentarium because they are safe and lower IOP with complementary mechanisms.’ - Dr Schwartz

IOP by  $-2.25$  mm Hg compared with the  $-0.1$  mm Hg reduction seen with timolol.

The Jupiter Study, an open-label, single-arm, 1-year safety study, included patients with OAG and OHT, three-quarters of whom had an IOP below 21 mm Hg. LBN achieved a significant ( $P = 0.001$ ) 26% reduction in IOP that was sustained over the course of the study.

The phase 3, 1-year Apollo and Lunar studies compared LBN 0.024% with timolol 0.5%. The results showed that, at 17 of 18 time points, the IOP in patients taking LBN was lower than in those taking timolol; the average IOP reduction was 32% compared with baseline. The IOP decrease was sustained to week 52 of the study.

### Clinical use

LBN has received approval for clinical use to treat OAG and OHT. A boon for patients is its once-daily dosing. The adverse effects seen with LBN are similar to those with

are being developed. NCX 470 is a NO-donating bimatoprost that caused significant IOP lowering compared with bimatoprost alone in preclinical studies. NCX 667 is a NO-donor drug without a prostaglandin. It reportedly lowered IOP significantly and sustained the decreases in rabbits and monkeys. NO-donating dorzolamide and brinzolamide are being studied.

“LBN 0.024%, which is currently available, lowers IOP better than timolol or latanoprost administered separately. NO donors are a new and safe addition to our glaucoma drug armamentarium because they are safe and lower IOP with complementary mechanisms. Additional research is underway into the effects of NO in the eye,” Dr Schwartz concluded.

#### DR GAIL F. SCHWARTZ, MD

E: [schwartzgf@gmail.com](mailto:schwartzgf@gmail.com)

Dr Schwartz receives lecture fees from Aerie Pharmaceuticals Inc. and Allergan, and is a consultant and advisor to Allergan.

in case you missed it

**PAGE 6**  
A small benefit from Brexit to Commonwealth ophthalmologists

**PAGE 12**  
An international encyclopedic database for IOL specifications

**PAGE 30**  
Biologics may offer systemic therapy option for uveitis

**PAGE 38**  
Vision-screening tools aid children's needs worldwide

# Biologics may offer systemic therapy option for patients with uveitis

One biologic response modifier has indication for uveitis; several in development

By Cheryl Guttman Krader;

Reviewed by Dr Eric B. Suhler



Dr Suhler

Quoting a line from 'Forrest Gump', Eric B. Suhler, MD, MPH, suggested that use of novel biologic response modifiers (BRMs) for uveitis in the earlier stages of study may be "like a box of chocolates". "You never know what you are going to get," explained Dr Suhler. One BRM is FDA approved for the treatment of uveitis, and it is hoped others will follow. However, more experience with this therapeutic category is needed before BRMs are adopted as first-line options, noted Dr Suhler, chief of ophthalmology, VA Portland Health Care System, and professor of ophthalmology and public health, Oregon Health and Science University, Portland, OR, USA.

Compared with standard systemic immunosuppressive drugs, BRMs represent more specific, targeted therapies with the potential for fewer side effects and greater effectiveness.

Compared with standard systemic immunosuppressive drugs, biologic response modifiers represent more specific, targeted therapies with the potential for fewer side effects and greater effectiveness.

In addition to the approved BRM, a number of biologics are being investigated as treatment for uveitis with some promising results.

Dr Suhler cautioned, however, that early findings are not always confirmed in larger studies, and with some of the biologics there is a need for more long-term safety information.

## ADALIMUMAB VS PLACEBO

VISUAL I 50%  
VISUAL II 43%  
reduced risk of treatment failure

### On-label option

Adalimumab (Humira, AbbVie), an anti-tumour necrosis factor- $\alpha$  (anti-TNF- $\alpha$ ) monoclonal antibody, was approved by the FDA for the treatment of adults with non-infectious intermediate, posterior, and panuveitis (NIIPP) in July 2016, based on the results of the multinational phase III VISUAL I and VISUAL II trials.

In October 2018, the indication was expanded to include children aged 2 and older based on results of the SYCAMORE study that investigated adalimumab plus methotrexate for uveitis in patients with juvenile

idiopathic arthritis.

VISUAL I enrolled patients with active uveitis despite systemic corticosteroid treatment and VISUAL II enrolled patients with corticosteroid-dependent, well-controlled disease. Treatment failure was analysed as the primary endpoint in both trials. Compared with placebo, adalimumab reduced the risk of treatment failure by 50% in VISUAL I and by 43% in VISUAL II.

VISUAL III was an open-label extension study that enrolled patients from the pivotal trials described previously who either had completed these studies successfully over 18 months or who were discontinued after meeting predefined treatment failure criteria. Results from VISUAL III showed the previously successfully treated cohort had sustained disease control while being maintained on

## IN SHORT

► **Treatment with a biologic response modifier (BRM) offers a more targeted approach to immunosuppressive therapy for uveitis than standard immunomodulatory drugs.**

subcutaneous adalimumab every other week while patients with active disease who started on adalimumab achieved rapid benefit despite tapering of their corticosteroid dose.

“This is a rare example of where the results of an open-label extension study were as compelling or maybe even more compelling than the results of the preceding randomised trials,” Dr Suhler said.

### Off-label TNF- $\alpha$ blockers

Infliximab (Remicade, Janssen) is another anti-TNF- $\alpha$  treatment that has demonstrated efficacy in the treatment of NIIPP uveitis. Given as an intravenous infusion every 8 weeks after an initial loading phase, infliximab may be an attractive option for patients who are expected to be non-compliant with self-administered subcutaneous injections, Dr Suhler said.

Limited data provide evidence that two other anti-TNF- $\alpha$  agents, certolizumab (Cimzia, UCB) and golimumab (Simponi, Janssen) are also effective treatment for NIIPP uveitis, in contradistinction to the anti-TNF- $\alpha$  fusion protein, etanercept (Enbrel, Amgen), which has been shown fairly clearly to not be effective in treatment of uveitis.

More convenient dosing is a feature of certolizumab and golimumab—both are administered monthly as a subcutaneous injection. Because pharmacokinetic data show low to negligible placental transfer of certolizumab, it is also considered as an attractive option for patients who are pregnant or wanting to become pregnant, Dr Suhler said.

Discussing safety, Dr Suhler noted that data from the rheumatology literature show treatment with anti-TNF- $\alpha$  agents may be associated with increased risks of malignancy and serious infections. The Systemic Immunosuppressive Therapy for Eye Diseases 1 (SITE-1) study also raised safety concerns, showing increased cancer-specific and all-cause mortality.

New information from SITE-2, which was presented later on the same day, however, showed that with increased follow-up from SITE-1, there did not seem to be an increased risk of malignancy in uveitis patients treated with TNF-blockers. As a bottom line, the risk of losing sight from uncontrolled uveitis is greater than the risks associated with anti-TNF- $\alpha$  treatment.

“All immunosuppressive drugs carry risk, and while there may be a slightly increased arithmetic risk of malignancy or infection with the anti-TNF- $\alpha$  drugs, the overall population

and appears to have particular benefit for controlling uveitic macular edema. In the STOP-UVEITIS study, tocilizumab was modestly effective for treating uveitis-related vitreous haze.

“Tocilizumab is much more effective for treating macular edema than inflammatory disease, but it may be worth trying tocilizumab to control inflammation when macular edema is present or in any patient with significant macular edema that is refractory to other therapies,” he said.

Results are being awaited from an NEI-sponsored study investigating

‘Given as an intravenous infusion every 8 weeks after an initial loading phase, infliximab may be an attractive option for patients who are expected to be non-compliant with self-administered subcutaneous injections.’ - Dr Suhler

attributable risk for these events is low, especially in comparison to the risk of vision loss for patients with poorly treated NIIPP uveitis, which is not low,” Dr Suhler said.

### Other BRMs

Rituximab (Rituxan, Genentech/Roche) is a commercially available B-cell blocker indicated for treating several diseases that are associated with scleritis, including rheumatoid arthritis and granulomatosis with polyangiitis, and microscopic polyangiitis.

Dr Suhler noted that it has also demonstrated efficacy for treatment of scleritis and orbital inflammation in case series from his own institution. In addition, rituximab is being used for treating vitreoretinal lymphoma and has demonstrated efficacy in limited series as treatment for uveitis and ocular cicatricial pemphigoid.

Tocilizumab (Actemra, Genentech/Roche), which blocks interleukin-6 (IL-6), has demonstrated efficacy in a case series of patients with juvenile idiopathic arthritis-associated uveitis,

the IL-12/23 blocker, ustekinumab (Stelara, Janssen), as a treatment for NIIPP uveitis, and an industry-sponsored multicentre randomised clinical trial is also under way investigating filgotinib (Gilead Sciences), a Janus kinase 1 (JAK) inhibitor.

“Filgotinib and other JAK inhibitors act at a very upstream point to block the transcription of pro-inflammatory cytokines and are also appealing because they can be given orally,” Dr Suhler said.

#### DR ERIC B. SUHLER, MD, MPH

E: [suhlere@ohsu.edu](mailto:suhlere@ohsu.edu)

This article was adapted from Dr Suhler's presentation during Uveitis Subspecialty Day at the 2018 meeting of the American Academy of Ophthalmology. He is a consultant to, receives lecture fees, and/or receives grant support from AbbVie, Aldeyra, EyeGate, EyePoint, Gilead Sciences, and Santen, and received previous support relevant to this article from Centocor and Genentech.

# Sustained-release corticosteroid expands armamentarium for uveitis

FA implant effective in lowering recurrence rates through 12-month follow-up

By *Cheryl Guttman Krader;*

Reviewed by  
*Dr David Callanan*



Dr Callanan

Following the FDA approval of the fluocinolone acetonide (FA) 0.18 mg intravitreal implant (Yutiq, EyePoint Pharmaceuticals) for the treatment of chronic non-infectious uveitis affecting the posterior segment of the eye in October 2018, the product was launched for U.S. commercial use in February 2019.

According to uveitis specialist, David Callanan, MD, access to the sustained-release corticosteroid implant is a welcome development because it provides clinicians with another great tool for treating appropriately selected patients affected by this sight-threatening disease.

“Every uveitis patient with posterior uveitis is unique, and individuals may respond differently to different medications,” said Dr Callanan, partner, Texas Retina Associates, and clinical professor of ophthalmology, University of Texas Southwestern Medical School, Dallas. “Locally administered corticosteroids, however, are generally very effective, and the ability to treat locally is important, especially for avoiding exposure to toxicities of

## IN SHORT

► **A new fluocinolone acetonide intravitreal implant (Yutiq, EyePoint Pharmaceuticals) that is expected to release a fixed-corticosteroid dose for 3 years is now commercially available in the US for the treatment of chronic non-infectious uveitis affecting the posterior segment of the eye.**

systemic medications in patients who do not have associated extraocular findings or for those whose uveitis is not responding adequately to systemic immunomodulatory therapy.”

“Phase III study results demonstrate that the new FA implant was effective for lowering recurrence rates through the available 6 and 12 months of follow-up, and the safety data on IOP elevation are encouraging so far,” he said. “The trials are ongoing, and we look forward to longer-term findings.”

The new FA implant uses a non-bioerodible, micro-insert platform that is designed to release a daily FA dose of 0.25 mcg over 3 years. The micro-insert is injected into the vitreous through the pars plana using a preloaded sterile applicator fitted with a 25-gauge needle. The injection is done in an in-office procedure akin to that used for intravitreal injections of anti-VEGF medications or dexamethasone 0.7 mg intravitreal implant (Ozurdex, Allergan).

“Unlike the previously available FA 0.59 mg implant (Retisert, Bausch + Lomb), intravitreal placement of the new FA product does not have to be done in the operating room,” Dr Callanan said. “Compared with the dexamethasone implant, the new FA implant is longer acting and therefore holds promise for maintaining remission with fewer re-injections.”

“Although the benefit of the dexamethasone implant (Ozurdex, Allergan) persisted for about 6 months in its pivotal clinical trial, clinical experience shows that efficacy can be lost after 3 months in quite a few patients,” he said. “Our aim in treating

**(FIGURE 1) The new fluocinolone acetonide (FA) 0.18 mg intravitreal implant uses a non-bioerodible, micro-insert platform that is designed to release a daily FA dose of 0.25 mcg over 3 years. David Callanan, MD, noted the minute size of the implant probably explains why the majority of patients do not seem to be aware of its presence in the eye.**

(Image courtesy of EyePoint Pharmaceuticals)



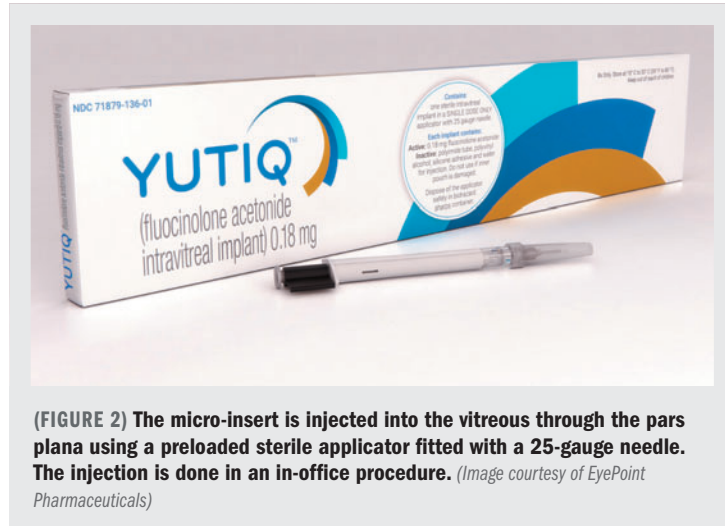


uveitis is to maintain quiescence and eliminate repeated flares that can lead to permanent tissue damage, and achieving that goal with the dexamethasone implant may carry a relatively high injection burden for some patients.”

### Clinical trial results

In two phase III trials, patients with non-infectious posterior uveitis were randomly assigned to treatment with the FA 0.18 mg implant or sham injection. Eligible patients had been affected by posterior uveitis for at least 1 year and experienced at least 2 separate recurrences requiring treatment with systemic medication (corticosteroid or immunosuppressive medications) or local corticosteroid injections (intraocular or periocular) or had received systemic therapy for at least 3 months or at least 2 local corticosteroid injections during the previous 12 months.

The rate of recurrent uveitis flares at month 6 was analysed as the primary endpoint and was significantly lower ( $p < 0.01$ ) in both studies in the FA group compared



**(FIGURE 2) The micro-insert is injected into the vitreous through the pars plana using a preloaded sterile applicator fitted with a 25-gauge needle. The injection is done in an in-office procedure. (Image courtesy of EyePoint Pharmaceuticals)**

through 12 months showed that the mean IOP increase was 1.3 mm Hg in the FA implant group and 0.2 mm Hg for the controls in one study and 2.0 mm Hg for the FA implant group and 0.0 mm Hg in the control group in the other trial. In a pooled analysis, the percentages of patients requiring any IOP-lowering medication and undergoing surgery for elevated IOP

that the older FA implant is surgically sewn into the pars plana close to the crystalline lens and ciliary processes. The new FA implant (Yutiq) is also a lower dose than the previous 0.59 FA implant (Retisert), he added.

Dr Callanan noted the minute size of the implant probably explains why the majority of patients do not seem to be aware of its presence in the eye.

‘Every uveitis patient with posterior uveitis is unique, and individuals may respond differently to different medications.’ – Dr Callanan

with the control group (18.4% versus 78.6% and 21.8% versus 53.8%). A statistically significant difference ( $p < 0.01$ ) in the recurrence rate favoring the FA implant group over the control group was also achieved at month 12 (27.6% versus 85.7% and 32.7% versus 59.6%) ( $p < 0.01$  for all comparisons of FA versus sham).

“Based on the statistical plan that was designed for trial robustness, patients who missed the 6-month follow-up visit were counted as having a recurrence, and for that reason, the recurrence rates in the FA group may be artificially high,” Dr Callanan said.

The safety review for data collected

were similar in the FA implant and control groups. Rates of cataract surgery in the two studies were 33.3 and 18.0% in the FA implant group, and 4.8 and 8.6% for the control group.

“The prescribing information for the FA 0.59 mg implant (Retisert) notes that based on clinical trial data, about 77% of patients will require IOP-lowering medications and 37% of patients will require glaucoma filtering surgery within 3 years after implantation,” he said.

Early data with the new FA implant suggest IOP elevation may be a less significant issue. A possible explanation for the difference may be

### Patient selection

Dr Callanan said that the ideal candidate for treatment with the new FA implant is a pseudophakic patient with chronic non-infectious posterior uveitis who has demonstrated a therapeutic response to prior local corticosteroid treatment without significant IOP.

#### DR DAVID CALLANAN, MD

E: [dcallanan@texasretina.com](mailto:dcallanan@texasretina.com)

Dr Callanan is an investigator in one of the phase III FA 0.18 mg implant clinical trials and is a consultant to EyePoint Pharmaceuticals.

# Managing uveitic macular oedema

Intravitreal treatments superior for regional treatment of disorder

By Lynda Charters;

Reviewed by  
Dr Jennifer E. Thorne



Dr Thorne

**M**acular oedema is a common complication in patients with uveitis—so much so that about 40% of patients in the Multicenter Uveitis Steroid Treatment (MUST) trial had baseline uveitic macular oedema (UMO). Although it can be treated and controlled, macular oedema also can be stubborn, require additional treatment and, worse yet, compromise sight.

The results of the PeriOcular versus INTravitreal corticosteroids for Uveitic Macular Oedema (POINT) study—a comparison of the regional go-to corticosteroids for UMO—indicated that direct injection of corticosteroids into the eye was superior to a therapy that is administered periorcularly, said Jennifer E. Thorne, MD, PhD.

Interestingly, an intravitreal dexamethasone implant was not associated with lower rates of IOP elevations as expected.

This study originated out of the recognition that few comparisons of the common treatments for UMO had been undertaken, and the best and safest of the regional corticosteroids had yet to be determined, said Dr Thorne, the Cross Family Professor of Ophthalmology and chief of the Division of Ocular Immunology, Wilmer Eye Institute, and professor of epidemiology, Johns Hopkins Bloomberg School of Public Health, Baltimore, MD, USA.

Therapies frequently used in this patient population

## IN SHORT

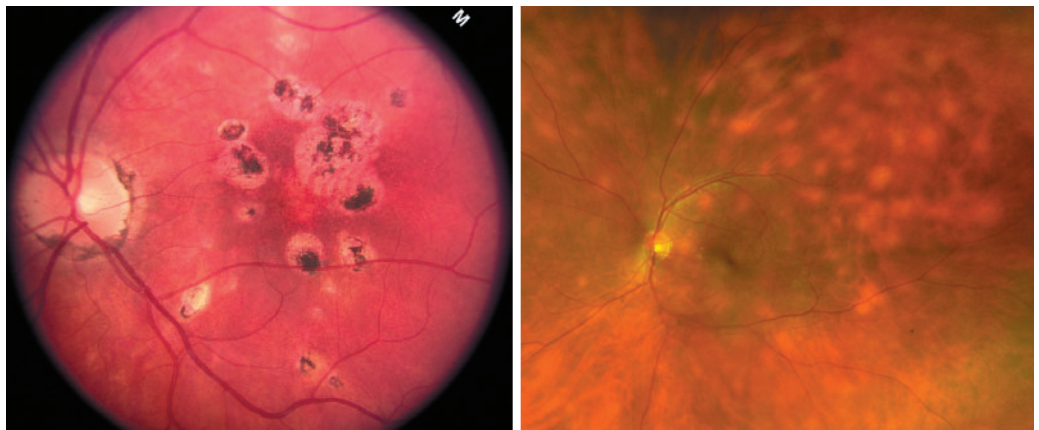
► **Intravitreal injections of triamcinolone acetonide and intravitreal dexamethasone implant achieve better results than periorcular triamcinolone acetonide in patients with UMO.**

are periorcularly administered triamcinolone acetonide (Kenalog, Bristol-Myers Squibb), intravitreally administered triamcinolone acetonide (Triesence, Alcon Laboratories) and the intravitreal dexamethasone implant (Ozurdex, Allergan), and they all provide good results. However, head-to-head comparisons of these three drugs are limited.

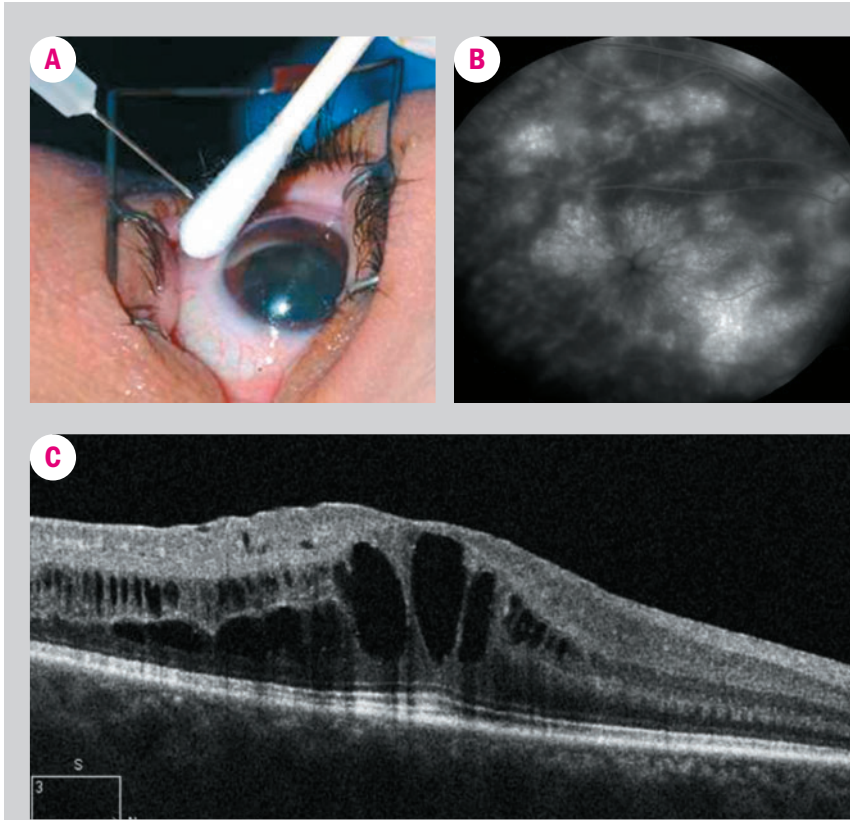
## Diving deeper

The POINT study hypothesised that intravitreal triamcinolone and the intravitreal dexamethasone sustained-release implant would be better for treating UMO than the periorcularly administered triamcinolone, and the dexamethasone implant would not be inferior to intravitreal triamcinolone.

The study also hypothesised the dexamethasone implant would be associated with a low rate of IOP elevations compared with intravitreal triamcinolone. The 192 patients with UMO in this multicentre trial were randomly assigned to one of three treatments:



**(FIGURE 1)** Left: Fundus photo of an eye with multifocal choroiditis with macular oedema. Right: Fundus photograph of Birdshot chorioretinitis with macular oedema.



**(FIGURE 2)**

- A.** Intravitreal injection of corticosteroids.
- B.** Fluorescein angiogram of the right eye demonstrating cystoid macular oedema.
- C.** Optical coherence tomography image of uveitic macular oedema.

(Images courtesy of Michael Altaweel, MD, on behalf of the MUST research group)

(1) periocular triamcinolone 40 mg (74 eyes), (2) intravitreal triamcinolone 4 mg (82 eyes), or (3) the intravitreal dexamethasone implant 0.7 mg (79 eyes).

Patients underwent ophthalmic examinations with optical coherence tomography (OCT) testing at baseline and at 4, 8, 12, 20 and 24 weeks after the start of treatment. The investigators recently published their findings (*Ophthalmology* 2019;126:283-295).

The primary study outcome compared the proportion of improvement of OCT central subfield thickness from baseline to the 8-week primary outcome visit.

Secondary outcomes included a >20% improvement in and resolution of macular oedema on OCT, best-corrected visual acuity (BCVA), and the IOP events over the 24-week study, according to Dr Thorne.

At the primary outcome visit,

the macular oedema improved in all treatment groups. The injections of the two intravitreally administered treatments resulted in greater reductions ( $p < 0.0001$ ) in UMO at 8 weeks compared with the periocularly administered triamcinolone; no significant difference was seen between the two intravitreal treatments at 8 weeks.

The decreases in the macular oedema obtained with intravitreal triamcinolone, intravitreal implant, and periocular triamcinolone were 39, 46 and 23%, respectively.

BCVA improved in all three groups, but the intravitreal drugs were superior to periocular therapy. Intravitreal triamcinolone and the dexamethasone implant resulted in significant ( $p < 0.004$ ) improvements in BCVA that were 5 letters greater than in the periocular drug group at the 8-week evaluation.

The risk of an IOP elevation was greater in the intravitreally injected

groups when compared with the periocular group, but the occurrence of IOP elevations over 30 mm Hg were low for all three groups. The dexamethasone implant had risks of IOP elevation similar to intravitreal triamcinolone.

The authors concluded that intravitreal triamcinolone acetate and the dexamethasone implant were superior to periocular triamcinolone for treating UMO with modest increases in the risk of IOP elevation. This risk did not differ significantly between intravitreal treatments.

**DR JENNIFER E. THORNE, MD, PHD**

**E:** [jthorne@jhmi.edu](mailto:jthorne@jhmi.edu)

This article was adapted from Dr Thorne's presentation during Uveitis Subspecialty Day at the 2018 meeting of the American Academy of Ophthalmology. This study was supported by grants from National Eye Institute/ National Institutes of Health and Allergan. Dr Thorne is on the advisory boards for AbbVie, Clearside, and Santen, and is a consultant for Gilead and NightstaRx.

# Complex retinal detachment in presumed genetic vitreoretinopathy

Optical coherence tomography (OCT) allows better surgical results

**By Prof. Matthias D. Becker and Dr Florian A. Heussen**



Prof. Becker



Dr Heussen

**C**omplex intraoperative conditions can simulate vitreoretinal changes, which may have fatal consequences and significantly influence the visual outcome of surgery due to poor intraoperative decision-making.

When the eye is filled with air prior to the insertion of silicone oil, light reflexes can significantly disturb the surgeon's vision. When a patient suffers from one of the rare genetic vitreoretinopathies like Stickler syndrome, there is an added confusion because a sign of vitreoretinopathies may be whitening of the retina, which simulates subretinal fluid, even when it is still attached.

Therefore, it can be unclear whether the retina is detached and needs additional attention or whether the surgeon can move forward with inserting the silicone oil.

Visualising retinal structures in greater detail with intraoperative optical coherence tomography (OCT) can help the surgeon to detect and perform scans during surgery without switching surgical instruments that can interrupt the workflow.

However, intraoperative OCT devices are rare in retinal practices and specific application fields are still under research. OCT technology allows surgeons to view transparent structures in high resolution, which allows better surgical results.

This complex case presentation proves the relevance of intraoperative OCT in complex retinal surgeries.

## Case presentation

An 11-year-old boy presented on August 18, 2018, with a history of vision loss in his left eye that he detected 1 week prior.

He suffered from high myopia in both eyes and was wearing spectacles with -10 D correction.

In his right eye, with spectacles, he had 60% vision, and his left eye was counting fingers because of an almost complete rhegmatogenous retinal detachment, resulting from several large retinal breaks. In his right eye, he had peripheral retinal degeneration.

Realising that this was extremely unusual for

an 11-year-old boy, we suspected a genetic disease that can cause retinal detachment in children, such as Stickler syndrome. Stickler syndrome is a hereditary condition with many signs and symptoms, one of which is eye abnormalities. These patients can suffer from high myopia, abnormal vitreous, increased intraocular pressure, cataracts and retinal detachment. We know that some of these

OCT technology allows surgeons to view transparent structures in high resolution, which allows better surgical results.

abnormalities can certainly cause impaired vision or blindness.

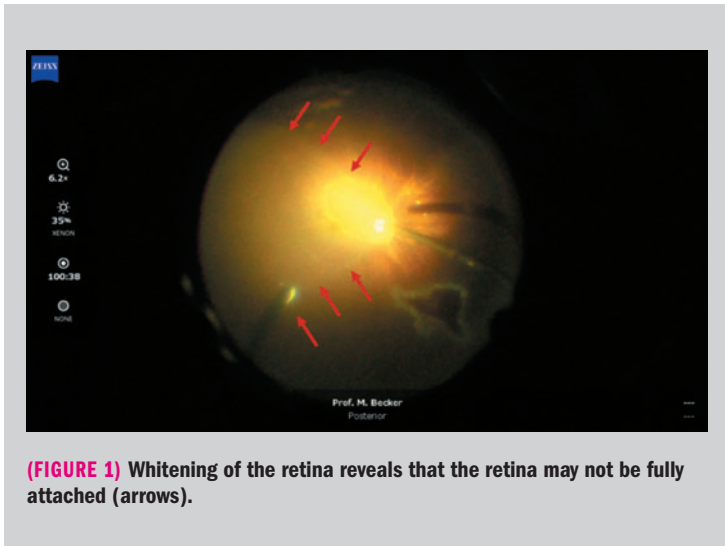
## SURGERY

Our surgical plan was to perform a 23 G vitrectomy with an encircling band and silicone oil tamponade. We placed the encircling band first, and then started the vitrectomy. Through the viewing system, we could visualise the size of several very large peripheral retinal breaks.

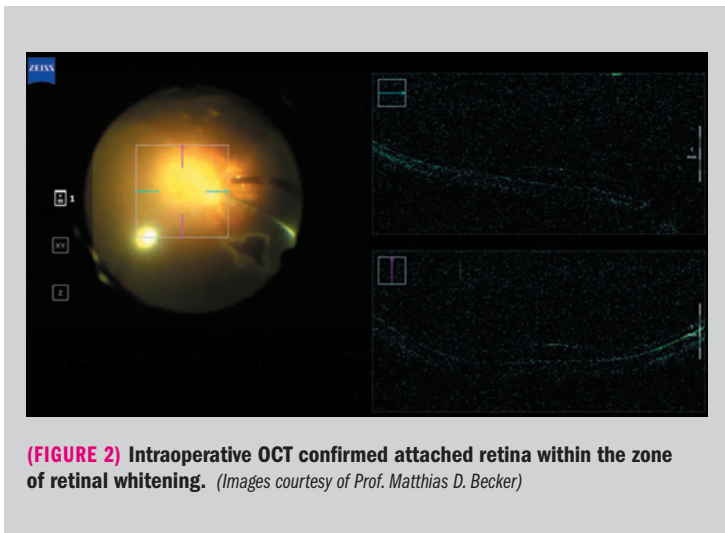
There was one connection in the retina at 11 o'clock and then more at the nasal superior periphery. We filled the eye with heavy liquid, perfluorodecalin, to get the retina re-attached. Prior to performing a direct exchange of silicone oil against heavy liquid, we applied laser coagulation to the retinal breaks.

## IN SHORT

► A case study is presented that shows the relevance of intraoperative optical coherence tomography (OCT) in complex retinal surgeries, and how better surgical results can be obtained by using this technology.



**(FIGURE 1)** Whitening of the retina reveals that the retina may not be fully attached (arrows).



**(FIGURE 2)** Intraoperative OCT confirmed attached retina within the zone of retinal whitening. (Images courtesy of Prof. Matthias D. Becker)

At this stage of the surgery, we were not sure whether retinal breaks still existed due to the whitening that extended over the macula to the temporal periphery.

Through use of intraoperative OCT (Lumera 700; Carl Zeiss Meditec), we could confirm that the retina was indeed attached and that we could continue with the silicone fill.

The whitening was interpreted as possible intraretinal edema as a reaction of the patient's vitreoretinopathy to the retinal detachment and not subretinal fluid,

which was confirmed on day 1 by OCT.

### POSTOPERATIVE RESULTS

The patient's visual acuity increased to 30% at the 4-week postoperative visit. The retina was attached in the silicone oil and we observed scarring of the laser spots.

Eight weeks postoperatively, we planned for silicone oil removal and the retina remained attached. The patient's vision was 30–40%, which was an excellent result following a complete retinal detachment.

### Discussion

Incorporating intraoperative OCT during vitreoretinal surgery is consistently helpful for decision

Being able to instantly monitor surgical decisions, progress and outcomes can make the difference between whether a patient has restored vision or not.

making during surgery, especially in complex vitreoretinal cases with reduced media transparency.

It can be an essential tool to determine whether the retina is re-attached if the surgeon is clinically suspicious, especially in cases of fresh retinal detachments where timing is essential and re-attaching the retina within 48 hours will increase chances of visual acuity returning to 100%. In those cases, it is important that the macula is attached to get the nutrition from the choroid underneath.

In cases where there is remaining subretinal fluid, the outcome is usually not as good as it is in attached macular situations.

Being able to instantly monitor surgical decisions, progress and outcomes can make the difference between whether a patient has restored vision or not.

#### PROF. MATTHIAS D. BECKER, MD, PHD, MSC

**E:** [Matthias.Becker@triemli.zuerich.ch](mailto:Matthias.Becker@triemli.zuerich.ch)  
*Professor of Ophthalmology and Ophthalmosurgery  
 Head of Department of Ophthalmology, University of Heidelberg.*

#### DR FLORIAN A. HEUSSEN, MD

**E:** [florian.heussen@triemli.zuerich.ch](mailto:florian.heussen@triemli.zuerich.ch)  
*Chief Physician, Eye Clinic, Triemli City Hospital, Zurich.*

# Novel vision-screening tools aid children's needs worldwide

New technologies help diagnosis in manner that is practical and adaptable

By Dr Robert W. Arnold



In U.S. paediatricians' offices and clinics, children can receive state-of-the-art, age-appropriate amblyopia vision screening. This starts with specific instrument-based estimation of amblyopia risk factors and ends with sensitive monocular visual acuity screening. Insurance plans typically cover these tests. Children from economically depressed and politically oppressed regions of the world also deserve screening to prevent treatable blindness. By implementing emerging technology, vision-screening benefits can be offered to all children.

The World Health Organization (WHO) has published guidelines for many types of health screenings (Table 1).<sup>1</sup> Amblyopia, the most common form of childhood vision impairment due to deficient brain learning of vision, fits the guidelines.<sup>2</sup> Vision screening, of course, must be balanced with other high-priority health concerns in a given region. Screening for amblyopia must also be matched with a local ability to provide spectacles, patches, and other treatments.

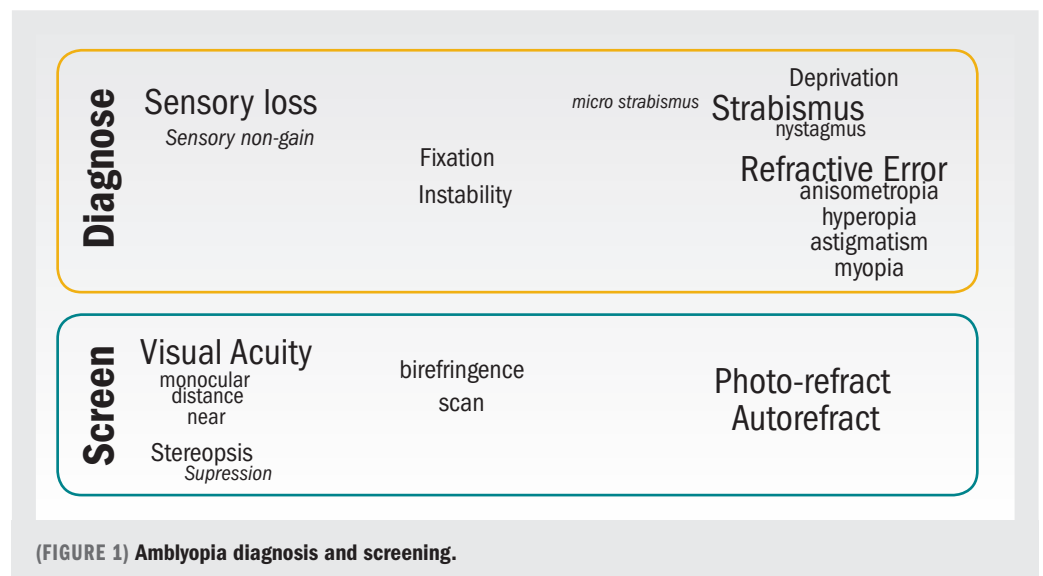
## Tools for medical missions

Advances have been made in tools that aid in amblyopia detection. This new technology is particularly helpful in developing countries.

Photoscreening analyses the pupillary red reflex produced by a near co-axial flash and lens. If both eyes are aligned on a camera lens with perfect focus, the pupil will be filled with a uniform red image in both eyes. If the eyes are defocused, a crescent of light appears in the pupil with the extent of encroachment related to the amount of refractive error. Asymmetric red reflex can also be produced by strabismus.

## IN SHORT

► **New child-friendly technologies that can be adapted to the setting in which they're required are helping in the diagnosis of vision disorders.**



# DOG 2019

Augenheilkunde:  
Unser Fach mit Zukunft  
26.–29.9. Berlin



Registrierung  
ab 1.2.2019

Abstracteinreichung  
1.2.–1.4.2019

[dog-kongress.de](http://dog-kongress.de)



(FIGURE 2) Plusoptix photoscreener in war zone in Burma. (Images courtesy of Dr Robert W. Arnold)



(FIGURE 3) A PDI check near-vision game.

Refractive errors, particularly anisometropia and high hyperopia, are amblyopia risk factors that are not apparent to the paediatrician (Figure 1). These vision disorders can be detected with photoscreening; early treatment with spectacles can profoundly reduce amblyopia.<sup>3</sup>

Today's photoscreeners implement multiple, sequential radial infrared flashes, with the original infrared photoscreener produced by the German company, Plusoptix. These photoscreeners have proven to be accurate, supported by peer-reviewed studies. Screening devices are particularly useful worldwide (Figure

## Table 1: WHO health screening guidelines

1	Important health problem	Amblyopia
2	Accepted treatment for recognised disease	Early sturdy spectacles
3	Facilities for diagnosis and treatment	Child friendly skiascopy
4	Suitable latent and symptomatic stage	First decade
5	Suitable test or examination	Photoscreen then PDI Check
6	Test acceptable to population	Quick and fun
7	Natural history of condition understood	
8	Agreed on policy on whom to treat	
9	Cost of finding economically balanced with overall health	
10	Case finding should be continuous process	AAP guidelines

2), in part because they implement readily available AA batteries and easily adjustable instrument referral criteria.

Criteria can be highly sensitive in regions where follow-up exams are simple and affordable.

Referral criteria can also be adjusted to be more specific; therefore, reducing referral rate and the number of false positive referrals.

### Recommendations

The American Academy of Pediatrics recommends a series of age-appropriate vision screenings during a child's first decade—the time when amblyopia occurs.<sup>4</sup>

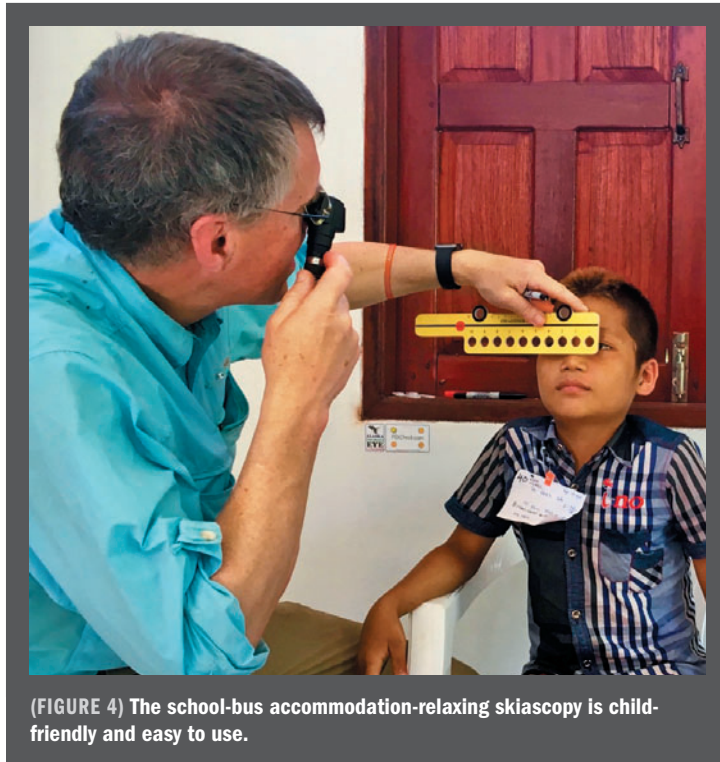Newborns should receive pupillary red reflex testing to look for congenital cataracts. Infants also should have fixation and cover testing to identify infantile esotropia. Starting at 12 months through kindergarten, specific photoscreening is quick and effective for detecting amblyopic risk factors.

After kindergarten, visual acuity screening is effective and can be a sensitive test if monocularly is assured. For distance acuity charts, monocularly is best assured with an occlusion patch.

'Vision screening, of course, must be balanced with other high-priority health concerns in a given region.' – Dr Arnold

Photoscreening with a Plusoptix device can be performed in less than 30 seconds per patient—which paediatric nurses and community screeners love. (The measurement itself takes less than a second.) Typical threshold monocular acuity screening takes more than





(FIGURE 4) The school-bus accommodation-relaxing skiascopy is child-friendly and easy to use.

5 minutes especially in younger children.  
Slow acuity screening is discouraging for busy paediatric

PDI Check can screen monocular acuity, stereo, and colour in about 100 seconds. Conventional patched acuity, plus booklet stereo

**‘New technology devices help in the diagnosis of vision disorders in a child-friendly manner that is not only practical but adaptable to various settings.’ - Dr Arnold**

offices or school screenings; a faster and more fun form of monocular acuity screening is warranted.

### **Nothing wrong with having some fun**

The Nintendo 3DS video game console has an autostereoscopic parallax barrier screen. PDI Check is a vision-screening game developed for the system allowing monocular acuity screening without occlusive patches and stereo screening without goggles (Figure 3).

and colour testing takes about 4 minutes.

Once children are referred from vision screening, their refraction must be measured to determine appropriate amblyopia therapy usually involving sturdy spectacles. Accurately estimating hyperopia and astigmatism can be daunting in young and/or developmentally delayed children.

Another new tool, marketed by Eye Care and Cure, consists of a horizontally oriented convex

skiascopy rack resembling a child-friendly school bus (Figure 4). By holding a higher plus lens over the non-retinoscoped eye, fogging allows accommodation almost as relaxed as that of cycloplegia.

### **Conclusion**

Children everywhere should have appropriate screening tests. Paediatricians want valid tests with sufficient sensitivity and specificity. The screening test also should be acceptable to the population—tests that take a long time and are not child-friendly are much less acceptable.

New technology devices help in the diagnosis of vision disorders in a child-friendly manner that is not only practical but adaptable to various settings.

### **REFERENCES**

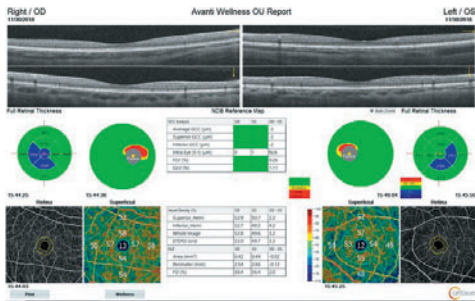
1. Wilson J, Junger G. Principles and practice of screening for disease. In: Public Health paper No. 34. Geneva: World Health Organization; 1968. <http://www.who.int/iris/handle/10665/37650>
2. Arnold RW. Towards worldwide amblyopia elimination- vision screening. *US Ophthalmic Review and European Ophthalmic Review*. 2009;2(1):91-98. doi. <http://doi.org/10.17925/EOR.2009.02.01.91>
3. Kirk VG, Clausen MM, Armitage MD, Arnold RW. Preverbal photoscreening for amblyogenic factors and outcomes in amblyopia treatment: early objective screening and visual acuities. *Arch Ophthalmol*. 2008;126:489-492.
4. Donahue S, Baker C. Visual system assessment in infants, children, and young adults by pediatricians. *Pediatrics*. 2016;137. <http://pediatrics.aappublications.org/content/pediatrics/137/1/e20153596.full.pdf>.

#### **DR ROBERT W. ARNOLD, MD, FAAP**

E: [eyedoc@alaska.net](mailto:eyedoc@alaska.net)

*Dr Arnold is a specialist in paediatric ophthalmology and strabismus. He is in practice at Alaska Children's Eye and Strabismus in Anchorage, AK. He did not indicate any relevant financial disclosures.*

## Novel Optovue OCTA technology enhances patient management



The latest optical coherence tomography angiography (OCTA) technology from Optovue is designed to offer a new dimension for enhanced patient management, according to the company.

The AngioWellness scan utilises Optovue's advanced AngioVue OCTA technology to quickly assess and diagnose new pathologies in patients, including diabetic patients and those who may be at risk for glaucoma.

AngioWellness combines structural information on retinal and ganglion cell thickness with objective metrics on retinal vasculature into one easy-to-read report. The first of its kind patient-monitoring tool was designed to help eye-care professionals offer a more comprehensive assessment of diabetic patients and glaucoma suspects, differentiate the practice with state-of-the-art technology, and identify patients who may need monitoring or medical eye care, according to the company.

For more information, go to [optovue.com](http://optovue.com)

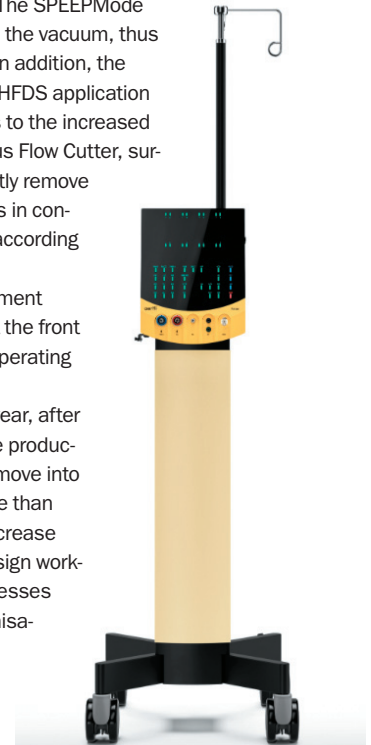
## Oertli presents Faros with new features; moves into expanded production facility

Oertli presents the Faros with its new features like the unique SLEEPMode. The SLEEPMode is able to control the flow and the vacuum, thus offering unbeatable fluidics. In addition, the Faros includes an integrated HFDS application for glaucoma surgery. Thanks to the increased cutting force of the Continuous Flow Cutter, surgeons can efficiently and gently remove the vitreous body what results in controlled working at the retina, according to the company.

On all models, most instrument ports are easily accessible at the front and making it easier for the operating room staff.

In other news, earlier this year, after 8 months of construction, the production employees were able to move into expanded premises with more than 1,000 square metres. The increase allowed the company to redesign workstations and make work processes more efficient, said the organisation in a prepared statement.

For more details, go to [oertli-instruments.com](http://oertli-instruments.com)



## Heidelberg introduces GMPE Hood Glaucoma Report to aid with diagnosis, management of disease

A new feature of the Glaucoma Module Premium Edition offers an intuitive and accurate approach to aid diagnosis and management of glaucoma. Heidelberg Engineering announced that the Hood Glaucoma Report is now available with a software update within the Spectralis OCT Glaucoma Module Premium Edition (GMPE).

The GMPE Hood Glaucoma Report highlights essential diagnostic information in an intuitive layout that enables a quick, yet comprehensive assessment.

Based on the diagnostic approach developed by Donald C. Hood, PhD, this report also accentuates the importance of high-resolution OCT B-scans and the unique anatomy of each eye, in the routine clinical diagnostic regimen.

Furthermore, this report allows clinicians to visualise functional and structural measurements along with high-resolution OCT B-scans and relate this information to 10-2 and 24-2 visual field points.

Taking advantage of the GMPE Anatomic Positioning System (APS), which tailors scan placement and orientation to each patient's individual anatomy, the report is optimised to serve as an intuitive and robust diagnostic aid.

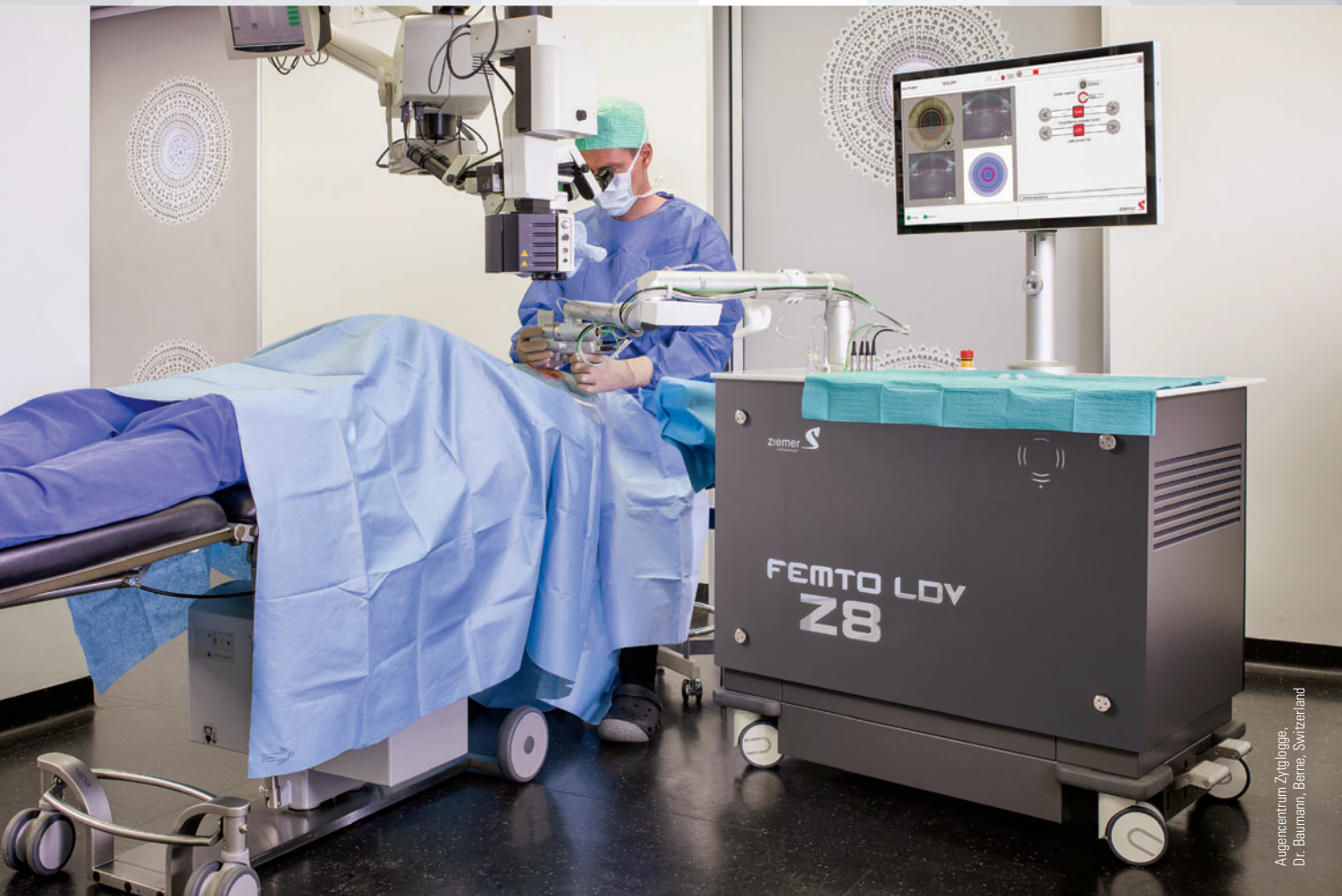
The unique semi-automated APS technology increases the precision and accuracy of results by ensuring that all glaucoma scans are anatomically aligned with the reference database and account for the individual configuration of axons in each eye.

For more information, go to [heidelbergengineering.com](http://heidelbergengineering.com)

# It's Time to make a Move

It has never been so simple to adapt new technology into your daily workflow. The truly mobile FEMTO LDV Z8 finally enables you to use next generation femtosecond laser technology for your cataract and refractive surgeries.

[www.femtoldv.com](http://www.femtoldv.com)



Augenzentrum Zyglodge,  
Dr. Baumann, Berne, Switzerland

**FEMTO LDV**  
**Z8** Cornea  
Cataract

ziemer   
OPHTHALMOLOGY

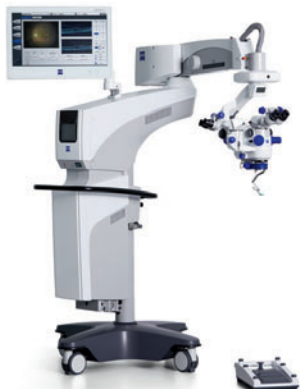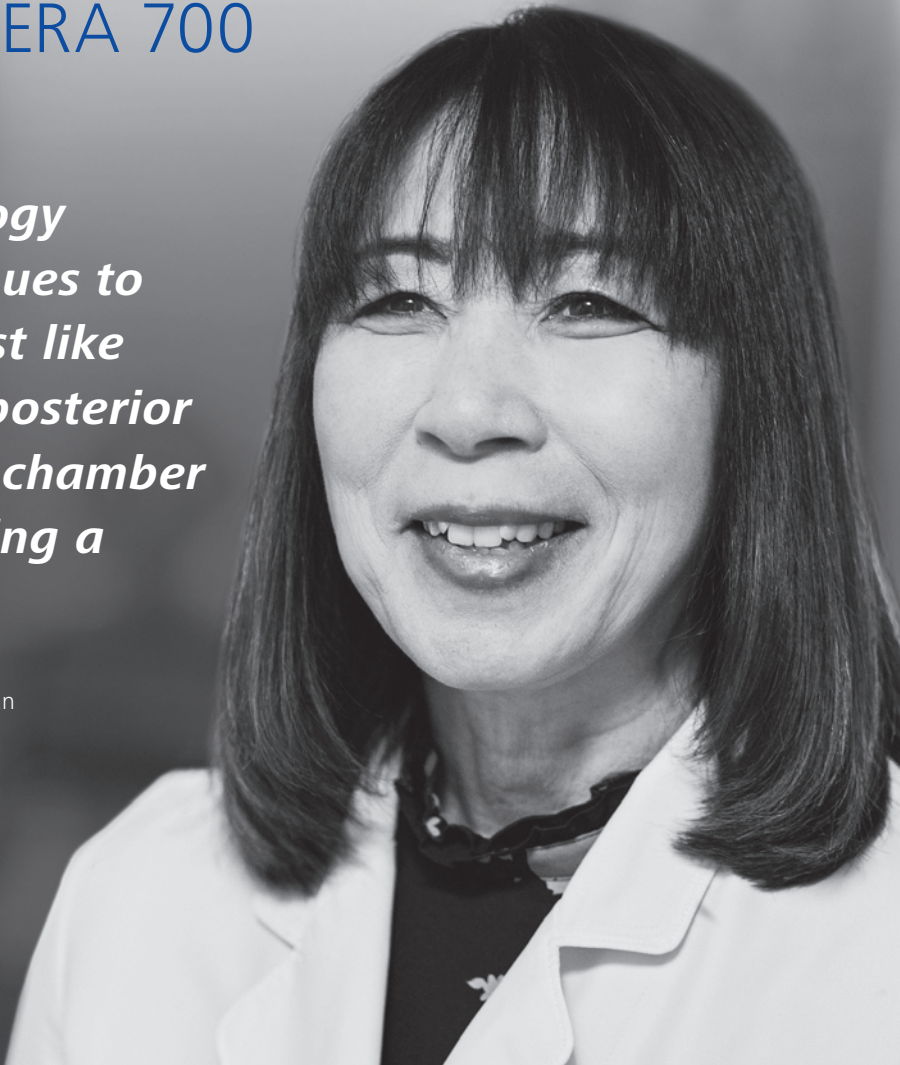
The FEMTO LDV Z8 is CE marked and FDA cleared for the use in the United States. For other countries, availability may be restricted due to regulatory requirements; please contact Ziemer for details.

# Seeing to succeed in cataract surgery.

ZEISS OPMI LUMERA 700

*»The superior technology of ZEISS optics continues to impress me today, just like when I first saw the posterior capsule and anterior chamber in the early 1980s using a ZEISS microscope.«*

Hiroko Bissen-Miyajima, MD  
Tokyo Dental College, Suidobashi Hospital, Japan



The quality of a technology can be measured by its ability to help improve outcomes. According to renowned cataract specialists like Dr. Bissen-Miyajima, when you see it, you immediately recognize the potential it holds – as with the superb optics and markerless toric IOL alignment capabilities with the OPMI LUMERA® 700 from ZEISS. We share her commitment to her calling. What's your calling?

[www.zeiss.com/mycalling](http://www.zeiss.com/mycalling)

